
ORIGINAL PAPER

RESEARCH OF PROGNOSTIC MARKERS OF PROLIFERATION AND APOPTOSIS IN PATIENTS WITH NODULAR GOITERS COMBINED WITH AUTOIMMUNE THYROIDITIS

M.I. SHEREMET¹, L.P. SYDORCHUK¹, V.O. SHIDLOVSKYI², A.D. BEDENYUK²

¹Department of Surgery, Bukovinian State Medical University

²Department of Surgery, I.Y. Horbachevskiy Ternopil State Medical University, Ukraine

SUMMARY

Background: Based on the results of a histological study of removed TG tissue NGAIT was found in 10, 4% of the patients (1, 2). At the same time, there are processes of both thyroid epithelium metaplasia and lymphoid tissue hyperplasia that, undoubtedly, can be considered as an optional precancerous condition (3-8). The option when cytomorphological and immunocytochemical examinations are carried out sequentially, using the same smear of a puncture material is optimal for PCE (9).

Methods: We have carried out an immunohistochemical study by means of monoclonal antibodies against Fas, FasL, Bcl-2, P53 and Ki67 antigens using the TG puncture material.

Results: The results showed the degree of proliferative activity in the thyroid tissue in NGAIT. We found a highly proliferative activity of lymphoid tissue, moderate proliferative activity of thyroid epithelial cells in the area of lymphoid infiltration and a low one – beyond the latter.

Conclusions: The pronounced expression of Fas and FasL on the thyroid epithelial cells in the area of lymphoid infiltration indirectly indicates that NGAIT causes the processes of thyroid epithelial cells apoptosis due to the immunity. Increasing the number of immunoreactive cells expressing Ki67 in the area of lymphoid infiltration and destruction of thyroid epithelial cells, are indicator of follicular epithelial regeneration as a compensatory-adaptive response of the organ. A pronounced bcl-2 expression in lymphocytes prevents the cells from apoptosis and prolongs the cell survival time. There was a high expression of p53 protein in the nuclei of thyroid epithelial cells and follicular lumina, which can be explained by mutations in the gene p53, which allows the cells to find tolerance to apoptotic action of the immune system effectors.

Abbreviations: NGAIT - nodular goiter combined with autoimmune thyroiditis, TG –thyroid gland, PCE – preoperative cytologic examination

Key words: nodular goiter combined with autoimmune thyroiditis, needle biopsy, apoptosis, proliferation, thyroid gland

RÉSUMÉ

Etude des marqueurs pronostiques de prolifération et d'apoptose chez les patients avec goître nodulaire combiné avec thyroïdite auto-immune

Contexte: A base des résultats d'une étude histologique du tissu GT éliminé, on a trouvé GNTAI dans 10, 4% des patients (1,2). Dans le même temps, ce sont des processus de métaplasie de l'épithélium thyroïdien et de l'hyperplasie des tissus lymphoïdes ce que, sans aucun doute, peut être considérée comme une condition précancéreuse facultative (3-8). L'option quand les examens cytomorphologiques et immunocytochimiques sont effectués séquentiellement, en utilisant le même frottis d'un matériel de ponction est optimale pour ECP (9).

Méthodes: Nous avons réalisé une étude immunohistochimique au moyen d'anticorps monoclonaux dirigés contre les antigènes Fas, FasL, Bcl-2, P53 et Ki67 en utilisant le matériel de ponction TG. **Résultats:** Les résultats ont montré le degré d'activité proliférative dans le tissu thyroïdien dans GNTAI. Nous avons trouvé une activité proliférative élevée du tissu lymphoïde, une activité proliférative modérée des cellules épithéliales de la thyroïde dans la zone d'infiltration lymphoïde et une autre faible - au-delà de cette dernière.

Conclusions: L'expression prononcée de Fas et FasL sur les cellules épithéliales thyroïdiennes dans la zone d'infiltration lymphoïde indique indirectement que le GNTAI provoque l'apoptose des cellules épithéliales thyroïdiennes due à l'immunité. L'augmentation du nombre de cellules immunoréactives exprimant Ki67 dans la zone d'infiltration lymphoïde et la destruction des cellules épithéliales thyroïdiennes, indiquent la régénération épithéliale folliculaire comme réponse d'adaptation compensatrice de l'organe. Une expression bcl-2 prononcée dans les lymphocytes empêche les cellules de pénétrer l'apoptose et prolonge le temps de survie cellulaire. Il y avait une forte expression de la protéine p53 dans les noyaux des cellules épithéliales de la thyroïde et du luminaire folliculaire, ce qui s'explique par des mutations

INTRODUCTION

In domestic medical literature there are many publications dealing with a study of nodular goiter combined with autoimmune thyroiditis (NGAIT) morphology (1-5). However, some issues remain unsolved including the role of autoimmune thyroiditis (AIT) in the development of tumour processes. According to the literature, AIT leads to metaplasia processes in the thyroid epithelium, hyperplasia of lymphoid tissue, which undoubtedly can be considered as an optional precancerous condition (4-9).

The information that papillary cancer and lymphomas occur three times more frequently in patients with NGAIT confirms this relationship (3,5-8).

The total accuracy of clinical, instrumental and laboratory diagnostic methods for assessment of morphological origin of nodular new growths in the TG even in the most daring conclusions does not exceed 80% (1-8). This result cannot be satisfactory either for surgeons (unjustified overdiagnosis of thyroid cancer) or for endocrinologists (inadequate and ill-timed selection of patients for surgical treatment) (10,11).

Unfortunately, the chemical reagents used in the preparation of drugs for morphological studies by a standard method, block most of the antigenic determinants. That is why immunocytochemical and morphological studies of the biopsy material are carried on individual drugs, which leads to additional needle biopsies and prevent from the morphological identification of the cells reacting with antibodies. Instead, the best for PCE is the option when cytomorphological and immunocytochemical study is carried out consistently on the same smear of a puncture material (12,13).

One of the mechanisms of malignant transformation and progression is a cell cycle dysregulation with apoptosis inhibition and proliferation activation (14-20).

Membrane receptors Fas and Fas-L as well as Bcl-2 proteins are usually attributed to apoptosis regulation markers; and some researchers give the key role to Bcl-2 in the regulation of apoptosis (14-15). Besides the proteins of bcl-2 class the suppressor gene p53 a nuclear phosphoprotein is also an apoptosis regulator (14,17,18). This gene may occur in two types: p53 "wild" type is believed to stimulate apoptosis, whereas mutant p53 has a similar effect on apoptosis, like Bcl-2 protein, which inhibits a programmed cell death. There are about 500 mutations of this gene (18). Mutations of this protein in patients with malignant, benign and autoimmune thyroid diseases have not been studied sufficiently (11,18).

dans le gène p53, permettant aux cellules de trouver une tolérance à l'action apoptotique des effecteurs du système immunitaire.

Abréviations: GNTAI - goître nodulaire combiné à une thyroïdite auto-immune, GT - glande thyroïde, ECP - examen cytologique préopératoire.

Mots clés: goître nodulaire combiné à thyroïdite auto-immune, biopsie à l'aiguille, apoptose, prolifération, glande thyroïde

In addition to the factors of apoptosis, proliferation activity provides a very important information to determine the nature of precancerous condition and its prognosis in terms of malignancy. One of immunohistochemical markers of proliferation is the antigen Ki-67. It was shown that Ki-67 is on the cellular nuclei at all stages of the life cycle except G0 and G1 early stages. After a cell leaves the mitotic cycle the antigen is not detected (14-17,20). The expression of these molecules one can be detected by standard immunocytochemical methods that are simple enough to integrate into the process of fine needle aspiration biopsy (FNAB). Using additional diagnostic techniques such as immunohistochemistry, can assist in the interpretation of "uncertain" changes, but currently there are not any universally adopted standard molecular markers (10,11,13,15).

It is quite necessary to solve these problems, because the correct choice of treatment strategy, timely surgical treatment and therefore the patient's survival depend largely on the accuracy of PCE (11,12).

That is why our aim was to study the processes of proliferation and apoptosis in thyroid puncture material under NGAIT using immunohistochemical method of investigation as well as determining the proliferative activity index.

MATERIAL AND METHODS

Between March 2015 to November 2016, at the Regional Endocrinology Center of Chernivtsi, 75 women with NGAIT have been examined. The age of patients ranged from 23 to 72 years.

The diagnosis was made clinically, by laboratory findings (thyroid peroxidase antibodies (TPOA) - 60-250 U/ml, thyroglobulin antibody (TGA) - 60-500 U/ml, thyroid-stimulating hormone (TSH) - 4-10 mU/L), by ultrasound and it was confirmed histologically after surgery.

The study did not include patients with hyperthyroidism, manifest hypothyroidism, arterial hypertension and cardiovascular disease, severe somatic pathology or after the menopause.

In all the patients were performed FNAB of the TG nodes controlled by ultrasound, while making at least three punctures of one node based on the fact that the percentage of inadequate punctates decreases depending on the number of punctures in the proportion when 1 puncture is 16%, 2 punctures are 5.3%, 3 punctures are 4%, 4 punctures are 2.6% (10).

While preparing the smears we used a method of restoration of antigen determinants activity developed and patented in the laboratory of the V. I. Komisarenko

endocrinology Institute. It enables to combine cytomorphological and immunocytochemical researches in one cytological preparation and provides a possibility to compare morphological and immunocytochemical characteristics of certain cellular elements (9).

This method gives good results on the drugs that were kept after staining no more than three days. After this period, the results were unstable, which is due to the oxidization processes in some chemical compounds in the air (9,12,13). To start an immunohistochemical reaction we used monoclonal antibodies to the following antigens: Mouse Human Ki-67 FITC Clone MIB-1; Anti-p53 Protein Monoclonal Antibody, FITC Conjugated, Clone DO-7; Mouse Anti-Human Apoptosis Regulator Bcl-2 (BCL2) Monoclonal, Unconjugated, Clone 124 antibody; Mouse Anti-Human CD95 Monoclonal Antibody, Unconjugated, Clone FAS18; Mouse Anti-Human CD95L Monoclonal Antibody, Unconjugated, Clone NOK-1 by Dako Denmark A/S. (Denmark)

The results of immunohistochemical reaction were evaluated by means of semiquantitative analysis, proposed by A.K. Khmelnytsky, according to the intensity of color "+ -" - small "+" - poor, "++" - moderate, "+++" - pronounced (13). Assessment of immunoreactive cells was calculated by the formula $(Fas, FasL, Bcl-2, P53) = N1 / N2 \times 100\%$, where N1 is the number of immunopositive cells to Fas, FasL, Bcl-2, P53 receptors, N2 - the total number of the cellular nuclei per 1 square millimeter. Assessment of the IPA was calculated by the formula $= NKi67 / N \text{ total} \times 100\%$ where NKi67 is the total number of nuclei immunopositive to the protein Ki67, N total is the total number of nuclei per 1 mm². Morphometric analysis was performed by means of the microscope Bresser BioScience Bino (Germany) with a digital camera Nikon DS-Fil, personal computer with installed software NIS-Elements F 3.2.

RESULTS AND DISCUSSION

The immunohistochemical study found that in all 75 cases (100%) the expression of Ki67 in thyroid epithelial cells was weak "+" and moderate "++" by nature, which manifested itself in the form of brown or light brown staining of nuclei in the thyroid epithelial cells. The

number of immunoreactive cells in the preparation was distributed unevenly. In the thyroid epithelial cells, near the areas of thyroid epithelium destruction, near lymphoid infiltration there was an increased expression of Ki67, IPA varied from 9.75 to 11.37% (median was 10.56%). In calculating the number of immunoreactive thyroid epithelial cells which were beyond the lymphoid infiltration, proliferation index reduced from 2.5 to 3.7% (median 3.15%). The lymphoid tissue was characterised by a brown colour and a high percentage of immunoreactive cells - from 93 to 95% (median 94%) (fig. 1, a).

We have also found a significant number of thyroid epithelial cells expressing Fas. The cytoplasmic membrane of thyroid epithelial cells was characterized by a brown «++» and deep brown «+++» colouring. The number of immunoreactive cells ranged from 47 to 63% (median 55%). It should be noted that a significant expression "+++" was observed in the areas with a pronounced lymphoid infiltration. FasL expression was higher "+++" in follicles and adjacent areas of lymphoid infiltration "++" which averaged 46.10% in the cell ratio (fig. 1 b, c). Co-expression of Fas and FasL in the areas of lymphoid follicles infiltration around thyroid epithelial cells indicates that Fas and FasL are not directly involved in apoptosis of thyroid epithelial cells but induce this process through the development of proapoptotic cytokines. Bcl-2 was slightly «-» expressed by the thyroid epithelium unlike the lymphoid tissue, the cytoplasm of which became brown «+++». When the lymphoid follicles were formed without clear boundaries, the lymphoid tissue of the thyroid gland was evenly coloured in the center and the periphery of follicles. When mature follicles were formed, there was no coloring in the center but the mantle zone of lymphoid follicles was intensely coloured. (fig. 1 d). The lymphoid tissue beyond the nodules was being intensely expressed by bcl-2 in the area of thyroid follicles and in the stroma of the gland. When analyzing the number of cells expressing bcl-2 we found from 87 to 93% of immunoreactive cells (median 90%).

There was a high expression of protein p53 in the nuclei of thyroid epithelial cells and in the follicular lumina, at the same time there was a prominent positive reaction with the nuclei coloured deep brown. (fig. 1e) Staining with this marker was local by nature, and there were no more than 7-9 nuclei in one field of view. The concentration of

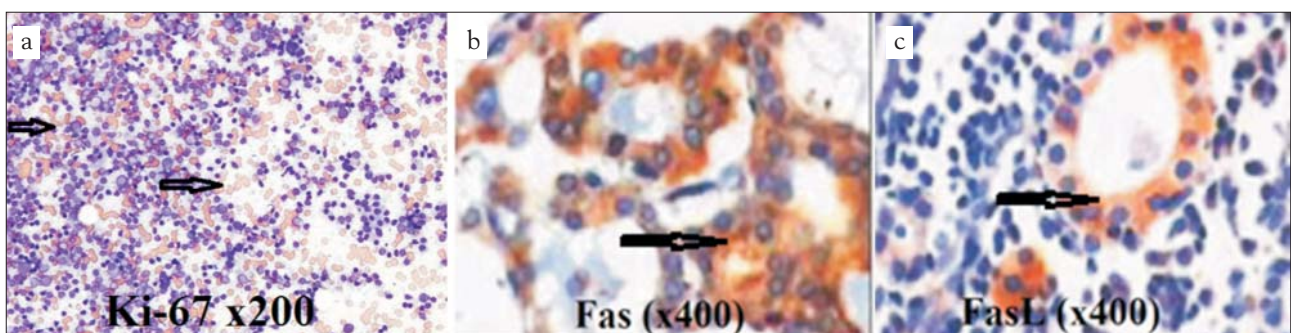
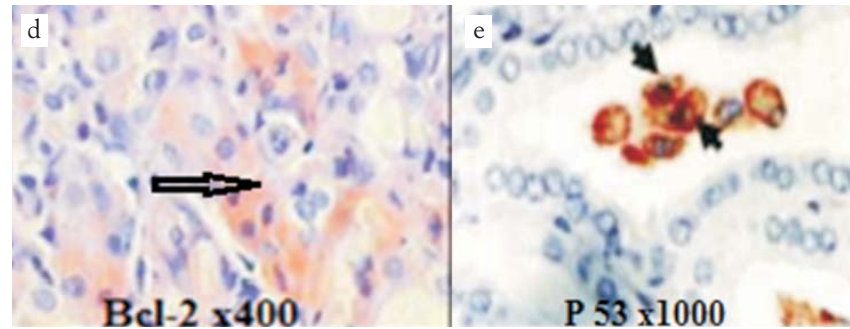


Figure 1 a,b,c

Figure 1 d,e



immunoreactive cells was from 64 to 71% (median 65, 5%). An increased density of p53-positive cells can be explained by mutations in the gene p53, which allows the cells to find tolerance to apoptotic action of the immune system effectors (14,15,18).

CONCLUSIONS

1. A pronounced expression of Fas and FasL on the thyroid epithelial cells, in the areas of lymphoid infiltration, indicates that in case of NGAIT immunologically caused processes of the thyroid epithelial cells apoptosis occur.
2. Co-expression of Fas and FasL in the areas of the lymphoid infiltration around the thyroid epithelial cells indicates that Fas and FasL are not directly involved in apoptosis of the thyroid epithelial cells, but they induce this process by producing pro-apoptotic cytokines.
3. Increasing the number of immunoreactive cells expressing Ki67 in the area of the lymphoid infiltration and destruction of the thyroid epithelial cells is indicator of the follicular epithelium regeneration as a compensatory-adaptive response of the organ.
4. A pronounced expression of bcl-2 in the lymphocytes prevents the cells from apoptosis as well as prolongs their survival time, which, undoubtedly, plays an important role in morphogenesis of the lymphoid tissue tumor diseases and prolonged processes of apoptosis and regeneration of the thyroid epithelium can also contribute to cancerogenesis.
5. An increased density of p53-positive cells can be explained by mutations of p53 gene, which allows the cells to find tolerance to an apoptotic action of the immune system effectors.

REFERENCES

1. Botasheva V.S., Kaloeva A.A., Erkenova L.D. Character of morphological changes during endemic goiter. (Published in Russian). Basic research. 2015; 1:699-703.
2. Tsyganenko O.S. Voroshchuk R.S. Immunomorphological reaction in the thyroid tissue in patients with autoimmune thyroiditis in combination with nodular goiter. Arta Medica. Nicholas Anestiadi, Tenth Congress of the Association of Surgeons of Moldova: Chisinau. 2007 October;4 (25):51-52.
3. Orlynskaia N.Y. Features histological and cytological methods using in the diagnosis of various cancer states of thyroid. Collection of materials of the All-Russian conference with international participation "Clinical morphology of thyroid cancer". (Published in Russian). Belgorod. 2004:42-43.
4. Berezkina I.S., Saprina T.V., Zima A.P. et al. The problem of molecular diagnostic test value in the differential diagnosis of a thyroid gland nodule. (Published in Russian). Clinical and experimental thyroidology. 2016;12(1):38-45.
5. Gulchiy M.V. Clinical peculiarities of thyroid cancer in combination with other thyroid pathologies and without. (Published in Ukrainian). Medicines Ukraine. 2007; 111:81-85.
6. Kim H.S. Y.J. Choi, Yun K.S. Features of papillary thyroid microcarcinoma in the presence and absence of lymphocytic thyroiditis. Endocrine Pathology. 2010; 21(3):149-153.
7. Di Pasquale H.M., Palazzo J.P., Rothstein J.L. Pathologic features of Hashimoto's associated papillary thyroid carcinoma. Hum. Pathol. 2001; 32 (1):24-30.
8. Bondarenko O.O., Shponka I.S., Gritsenko P.A. The use of tumor markers in the diagnosis of morphological epithelial tumors of thyroid gland. (Published in Ukrainian). Morphology. 2010;3(2): 12-16.
9. Bozhok Y.M., Tavokina L.V., Abramenko I.V., Belous N.I. Preparation of morphological preparations for immunohistochemical study. (Published in Ukrainian). UA. Patent UA 23098;1998.
10. Sheremet M.I., Shidlovskyy V.O., Sydorchuk L.P. Analysis of a process of peroxidation, caspase-3 and caspase-8 in patients with autoimmune thyroiditis. Journal of Education, Health and Sport. 2015; 5(11):117-125.
11. Sheremet M.I., Shidlovskyy V.O., Sydorchuk L.P. Assessment of proliferation and apoptosis markers in patients with autoimmune thyroiditis. Journal of Education, Health and Sport. 2016; 6 (1):179-188.
12. Zubev P.S. Place fine-needle aspiration biopsy in determining the indications for surgery in nodular colloid goiter. (Published in Russian). Remedium. Special Edition Endocrinology. 2005:93-94.
13. Khmel'nitsky D.C. Cytological and histological diagnosis of thyroid diseases: a guide. St. Petersburg., 2002:288.
14. Kazakov S.P., Kushlinsky N.Ye. The investigation of CD 95, p53, bcl-2 and Ki-67 markers in autoimmune thyroid pathology patients. First Joint Meeting of European National Societies of Immunology Under the auspices of EFIS and 16th European Congress of Immunology: ECI. 2006 Sept. 6-9; Paris, France: 547.
15. Ganchevska P., Murdjev K., Sarafian V. Expression of proliferative antigens in human thyroid diseases. Trakia Journal of Sciences. 2004; 2(1):16-20.
16. Yuan Zhou, Hong-Gang Jiang, Ning Lu et al. Expression of Ki67 in Papillary Thyroid Microcarcinoma and its Clinical Significance. Asian Pacific Journal of Cancer Prevention. 2015;16 (4):1605-1608.
17. Choudhury M, Singh S, Agarwal S. Diagnostic utility of Ki67 and p53 immunostaining on solitary thyroid nodule - a cytohistological and radionuclide scintigraphic study. Indian J Pathol Microbiol. 2011; 54 (3):472-475.
18. Chumakov P.M. The function of the p53 gene: the choice between life and death. Biochemistry. 2000; 65:34-47.
19. Sydorchuk LP, Amosova KM. Influence of pharmacogenetically determined treatment on parameters of peripheral hemodynamics in patients with arterial hypertension. The New Armenian Medical J. 2011; 5 (2):35-43.
20. Pujani M, Arora B, Pujani M, et al. Role of Ki-67 as a proliferative marker in lesions of thyroid. Indian J Cancer. 2010; 47 (3):304-307.