

# A CADAVERIC STUDY OF ANATOMICAL VARIATIONS OF THE NORMAL ARTERIAL PATTERN IN HELLENIC POPULATION

Eleni PANAGOULI<sup>1</sup>, Gregory TSOUCALAS<sup>2✉</sup>, Theodoros G PAPAIOANNOU<sup>3</sup>,  
Vasilios THOMAIDIS<sup>2</sup>, Aiki FISKA<sup>2</sup>, Dionysios VENIERATOS<sup>1</sup>, Panagiotis SKANDALAKIS<sup>1</sup>

<sup>1</sup> Department of Anatomy, Medical School, National and Kapodistrian University of Athens, Greece

<sup>2</sup> Department of Anatomy, School of Medicine, Democritus University of Thrace, Alexandroupolis, Greece

<sup>3</sup> First Dept. of Cardiology, Hippokration Hospital, Medical School, National and Kapodistrian University of Athens, Athens, Greece

Received 14 Oct 2018, Accepted 27 Nov 2018

<https://doi.org/10.31688/ABMU.2018.53.4.01>

## ABSTRACT

**Introduction.** Arterial variations may cause significant complications during diagnostic and interventional procedures.

**The objective of the study.** Our study examined 73 donated cadavers in the National and Kapodistrian University of Athens, in an effort to unearth possible artery alternations.

**Material and methods.** The major branches of the abdominal aorta, the arteries of the limbs and the neck were inquired.

**Results.** In 58.9% of the cadavers no arterial variation was found, whereas one, two and three alternations at the same cadaver were observed in 21.9%, 12.3% and 6.8% respectively. The most common anatomical variations were noted in the vascular branching of the celiac trunk found in 24.7% of the cadavers.

**Conclusions.** There was no statistically significant difference between the two genders concerning the frequency of the observed arterial variations ( $p < 0.05$ ).

## RÉSUMÉ

**Etude cadavérique des variations anatomiques d'un modèle artériel normal de la population Hellénique**

**Introduction.** Les variations artérielles peuvent entraîner des complications importantes lors de procédures de diagnostic et d'intervention.

**L'objectif de l'étude.** Notre étude a examiné 73 cadavres qui ont été donnés à l'Université Nationale et Kapodistrienne d'Athènes, dans le but de découvrir de possibles alternations des artères.

**Matériel et méthodes.** Les principales branches de l'aorte abdominale, les artères de la boîte et du cou ont été examinées.

**Résultats.** Aucune variation artérielle n'a été constatée chez 58,9% des cadavres, alors qu'une, deux et trois alternances chez le même cadavre ont été observées à 21,9%, 12,3% et 6,8% respectivement. Les variations anatomiques les plus courantes ont été observées dans la ramification vasculaire du tronc coélique retrouvée chez 24,7% des cadavres.

✉ Address for correspondence:

Gregory TSOUCALAS  
Department of Anatomy, School of Medicine, Democritus University of Thrace, Alexandroupolis, Greece  
Address: Ierolohiton 155, Agioi Anargyroi 38334, Volos, Greece  
Email: gregorytsoucalas@yahoo.gr; Phone 00306945298205

**Keywords:** artery variations, cadaveric study, celiac artery, superior mesenteric artery, inferior mesenteric artery, renal artery.

**Conclusions.** Il n'y avait pas de différence statistiquement significative entre les deux sexes concernant la fréquence des variations artérielles observées ( $p < 0,05$ ).

**Mots-clés:** variations artérielles, étude cadavérique, artère coeliaque, artère mésentérique supérieure, artère mésentérique inférieure, artère rénale.

## INTRODUCTION

The beauty and diversity of the human arterial tree attract the research and clinical interest of vascular and general surgeons, cardiologists, interventional radiologists and other medical and non-medical scientists. To learn its complexity presents a crux of its own. A better knowledge of anatomical variations of the normal human arterial pattern may improve surgical application and decrease complications. In reality, morphology and anatomical variations of the arteries are depicted in such a prevalence among humans that a comprehensive and illustrative awareness of arterial variations beyond of normal anatomy is crucial<sup>1</sup>.

Variations in the conduit arteries supplying organs and tissues with blood are usually harmless. Nevertheless, to correctly detect, understand and interpret both normal arterial trajectories and their possible changes is of great importance before any external intervention. On the other hand, some anatomical variations could present a negative effect concerning blood supply<sup>1</sup>. Vascular structure is the result of a complex biological process, genetically programmed and controlled, while various triggers during embryological evolution may result in anomalies which are usually considered as abnormalities. In large vessels, mainly, variations are due to the persistence of embryonic dispositions<sup>2</sup>. As the true frequency of altered patterns depends basically on the ability of the investigator-anatomist to recognize them, dissections require specialized personnel and in-depth comprehension of the possible alternations of the human cannulation<sup>3</sup>.

**THE OBJECTIVE OF OUR STUDY** was to investigate in a cadaveric series and present the possible variations in the main vessels of the human body and their clinical significance.

## MATERIAL AND METHODS

A summary of 73 embalmed human cadavers of Caucasian (Hellenic) origin (38 male and 35 female) was examined during routine educational dissection in cadavers donated at the Anatomy Department of the Medical School of the National and Kapodistrian

University of Athens. The cadavers derived from body donation with informed consent written and signed (with signature authentication) by the donor himself. The protocol for the present research had been approved by the ethics committee of our institution.

The following arteries were studied, in order to investigate the existence of anatomical variations: a) Major branches of the abdominal aorta: the celiac artery (CA), the superior and inferior mesenteric arteries (SMA & IMA), the renal arteries (RA), b) Arteries of the limbs: the profundi femoris arteries (PFA) and the profundi brachii arteries (PBA) bilaterally, and c) Arteries of the neck: brachiocephalic artery (BCA), and the vertebral arteries (VA) bilaterally.

Categorical variables are presented as absolute frequencies and percentages (%). Fischer's exact test and cross-tabulations were used to compare the frequencies of arterial variations between male and female cadavers. Statistical significance level was accepted for p-values less than 0.05. Statistical analysis was carried out using IBM SPSS Statistics for Windows version 25.0.

## RESULTS

The absolute frequency and the percentage of subjects with one, two, three or four anatomical variation(s) or without any variation are reported in Table 1. It was observed that 58.9% of the cadavers did not present any arterial variation, whereas one, two and three variations at the same cadaver were observed at 21.9%, 12.3% and 6.8% of the examined sample respectively.

The absolute frequency and percentage of each different type of the observed arterial variations are reported in Table 2. The most common anatomical variations that were determined in our cadaveric investigation were the vascular branching alternations of the CT found in 24.7% of the cadavers, the additional RA discovered in 20.5% (right RA 11%, left RA 9.6%) and variations of the left vertebral artery in 8.2%. Among these variations a complete absence of a vessel was observed. Thus, in two cadavers the CT (2.7%) was absent, in one the left PFA (1.4%) and in another one the BCA (1.4%). No variations were found in the SMA, right VA and right PFA.

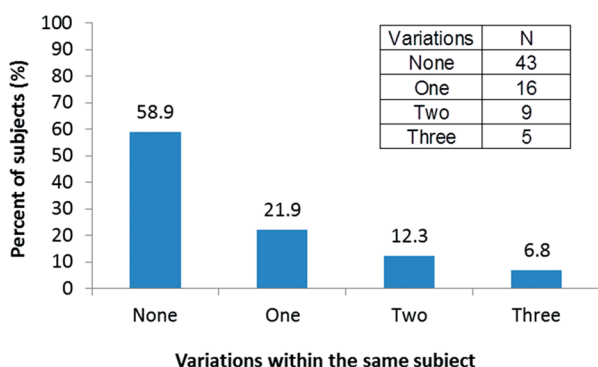
The absolute frequency and percentage of different combinations of arterial variations observed at the examined cadavers is reported in Table 3. Combination of variations of the celiac artery and unilateral ARA was the most frequent one (5.5%) with the next most frequent being the variation of the celiac artery combined with unilateral common trunk of the profunda brachii artery (2.75%). Finally, Table 4 provides the variations observed at each cadaver. The absolute frequency of variations observed at male and female cadavers are reported in Table 5. There was no statistically significant difference between the two genders concerning the frequency of the observed arterial variations ( $p < 0.05$ ).

**DISCUSSION**

Our team of anatomists firstly examined all major branches of the abdominal aorta. The celiac artery, or as more commonly referred the celiac trunk

(CT), constitutes a surgically significant splanchnic branch, the first of the abdominal aorta. CT is a short arterial segment which arises just below the aortic hiatus at the level of the T12/L1 vertebral bodies and trifurcates after a short course to the common hepatic, splenic, and left gastric arteries forming a tripod, known as „tripus Halleri“<sup>4,6</sup>. This tripod may be a true one with a common origin of all the three arteries, or a false one, where one of its branches – most commonly the left gastric artery- arises earlier (separate) along the celiac trunk. A series of classification attempts exist in the literature. Despite all anomalies reported on the normal pattern of the CT, several anatomical variations were also discussed. Thus, a series of cases noted the absence of one of its branches (bifurcation or incomplete CT), additional branches, common origin with the superior mesenteric artery (celiac-mesenteric trunk), common origin with the superior and inferior mesenteric artery (celiac-bimesenteric trunk) and total absence of the CT (Figure 1)<sup>7-10</sup>.

**Table 1.** Anatomical variations in cadavers arteries



**Table 2.** Absolute frequency and percentage of different types of anatomical variations

No.	Variation	Number	Percent (%)
1	celiac artery	18	24.7
2	right renal artery	8	11.0
3	left renal artery	7	9.6
4	left vertebral artery	6	8.2
5	left profunda femoral artery	4	5.5
6	right profunda brachii artery	3	4.1
7	left profunda brachii artery	2	2.7
8	brachiocephalic artery	2	2.7
9	inferior mesenteric artery	1	1.4
10	superior mesenteric artery	0	0.0
11	right profunda femoral artery	0	0.0
12	right vertebral artery	0	0.0

**Table 3.** Combinations of anatomical variations in cadaver's arteries

No	Combinations of anatomical variations	Percentage	No in total
1	Variation of the celiac artery and unilateral additional renal artery	5.5%	4/73
2	Two variations of the celiac artery	1.4 %	1/73
3	Bilateral additional renal artery	1.4 %	1/73
4	Variation of the celiac artery and unilateral common trunk of the profunda brachii artery	2.75%	2/73
5	Variation of the celiac and brachiocephalic artery	1.4 %	1/73
6	Common trunk of the profunda brachii artery bilateral	1.4 %	1/73
7	Variation of the celiac artery and absence of the profunda femoris artery	1.4 %	1/73
8	Variation of the celiac and inferior mesenteric artery and unilateral additional renal artery	1.4 %	1/73
9	Variation of the celiac artery, common trunk of the profunda brachii artery and unilateral additional renal artery	1.4 %	1/73
10	Variation of the celiac artery and bilateral additional renal artery	1.4 %	1/73
11	Two variations of the celiac artery and variation of the left vertebral artery and unilateral additional renal artery	1.4 %	1/73

**Table 4.** Anatomical variation(s) per cadaver

No	Sex	Variation(s)
1	F	Absence of the celiac trunk
2	M	Incomplete (false) celiac trunk, Additional left renal artery
3	M	Incomplete (false) celiac trunk, Common trunk of the right profunda brachii artery
4	F	Incomplete (false) celiac trunk, Additional right renal artery
5	M	Incomplete (false) celiac trunk
6	F	Incomplete (false) celiac trunk, Additional left renal artery
7	M	Incomplete (false) celiac trunk
8	M	Incomplete (false) celiac trunk, Additional left renal artery, Additional right renal artery
9	M	Additional left renal artery, Additional right renal artery
10	M	Additional right renal artery
11	F	Additional right renal artery
12	F	Additional right renal artery
13	M	Additional right renal artery
14	M	Absence of the profunda femoris artery
15	F	Origin of the left vertebral artery from the aortic arch
16	F	Origin of the left vertebral artery from the aortic arch
17	F	Origin of the left vertebral artery from the aortic arch
18	M	Origin of the left vertebral artery from the aortic arch
19	M	Double vertebral artery
20	M	Absence of the brachiocephalic artery
21	F	Additional right renal artery, Anomalous origin of right inferior phrenic artery from the celiac artery, Origin of the left vertebral artery from the aortic arch
22	F	Incomplete (false) celiac trunk, Additional left renal artery, Common trunk of the left profunda brachii artery
23	F	Common trunk of the right profunda brachii artery, Common trunk of the left profunda brachii artery
24	M	Incomplete (false) celiac trunk
25	M	Incomplete (false) celiac trunk, Anomalous origin of the lumbar artery from the celiac artery
26	F	Absence of the celiac trunk, Additional left renal artery (Origin of the additional renal artery from the left common iliac artery)
27	M	Incomplete (false) celiac trunk, Common trunk of the right profunda brachii artery
28	M	Incomplete (false) celiac trunk, Additional left renal artery, Origin of the inferior mesenteric artery from the left common iliac artery
29	F	Incomplete (false) celiac trunk, Large brachiocephalic artery
30	F	Double profunda femoris artery

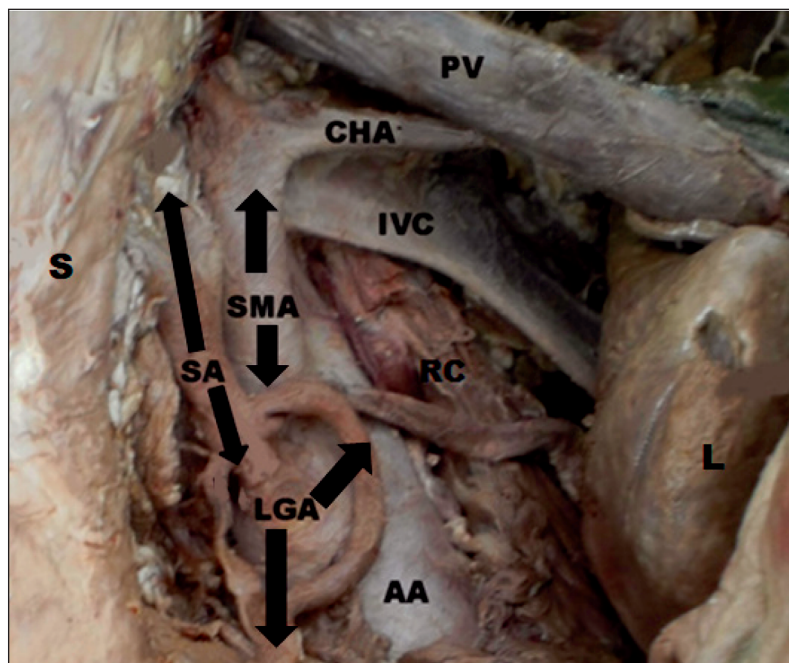
**Table 5.** Absolute frequency of variations observed at each gender. Percentages of males and females within each variation group are reported

Variation	MALES		FEMALES	
	N	%	N	%
celiac artery	11	61.1	7	39.9
right renal artery	4	50.0	4	50.0
left renal artery	4	57.1	3	42.9
left vertebral artery	2	33.3	4	66.7
right profunda brachii artery	2	66.7	1	33.3
left profunda brachii artery	0	0.0	2	100.0
left profunda femoral artery	1	25.0	3	75.0
inferior mesenteric artery	1	100.0	0	0.0
brachiocephalic artery	1	50.0	1	50.0
superior mesenteric artery	0	-	0	-
right profunda femoral artery	0	-	0	-
right vertebral artery	0	-	0	-

CT variation is found in approximately 10% of the general population, while an incomplete CT was reported in about 9.5% of the studied individuals<sup>11</sup>, with a complete absence of the trunk noted as a rare finding<sup>5,11-12</sup>. Our study demonstrated increased numbers concerning 2.7% for CT absence. On the other hand, we have encountered decreased percentage concerning the anomalous origin of the inferior phrenic artery from the celiac artery which is reported in literature in high percentages from 32.2 up to 42.2%<sup>13</sup>, while we report only a 1.4%. Anomalous origin of the lumbar artery from the celiac artery reported as an uncommon variation<sup>5</sup>, confirmed by our study which notes 1.4% for this branching alternation. The rest of the variations concerned the existence of a false tripod. Knowledge of the CT anatomy and its branching pattern, normal and varied, is of great importance due to number of current medical procedures in the area, such as vascular operations (treatment of abdominal aortic aneurysms), abdominal and visceral surgery (hepatic, pancreatic, and esophagogastric operations) and organ transplantations<sup>4,5</sup>.

The superior mesenteric artery (SMA) originates from the abdominal aorta approximately 1 cm below the CT at the level of the L1/2 intervertebral disc. Although the variations in this artery are very common and numerous we have detected no anatomical variations in none of our dissected cadavers. The inferior mesenteric artery (IMA) arises from the front of the abdominal aorta (its third main branch) behind the third-horizontal part of the duodenum at the level





**Figure 1.** Absence of celiac trunk (cadaver no 1). AA: abdominal aorta, SA: splenic artery, CHA: common hepatic artery, LGA: left gastric artery, SMA: superior mesenteric artery, IVC: inferior vena cava, PV: portal vein, S: stomach, L: liver, RC: right crus of the diaphragm, CT: celiac trunk.

of L3 vertebra, about 3-4 cm above the termination (bifurcation) of the abdominal aorta. It descends anteriorly to the aorta and then passes to the left as it continues inferiorly. Its branching includes the left colic artery, several sigmoid arteries and the superior rectal artery. Although IMA's divisional branches showed important variability in terms of distance to the origin and repartition, its anatomical variations are rare<sup>14-15</sup>. We report only one variation of the IMA, concerning its origin from the left common iliac artery (1.4%). For the diagnosis of intestinal angina and ischemic colitis is essential for the radiologist to understand all possible variant of the IMA. The same apply for a surgeon in the case of intestinal operations (malignancies, compressions, occlusive disease, IMA reimplantation)<sup>16</sup>.

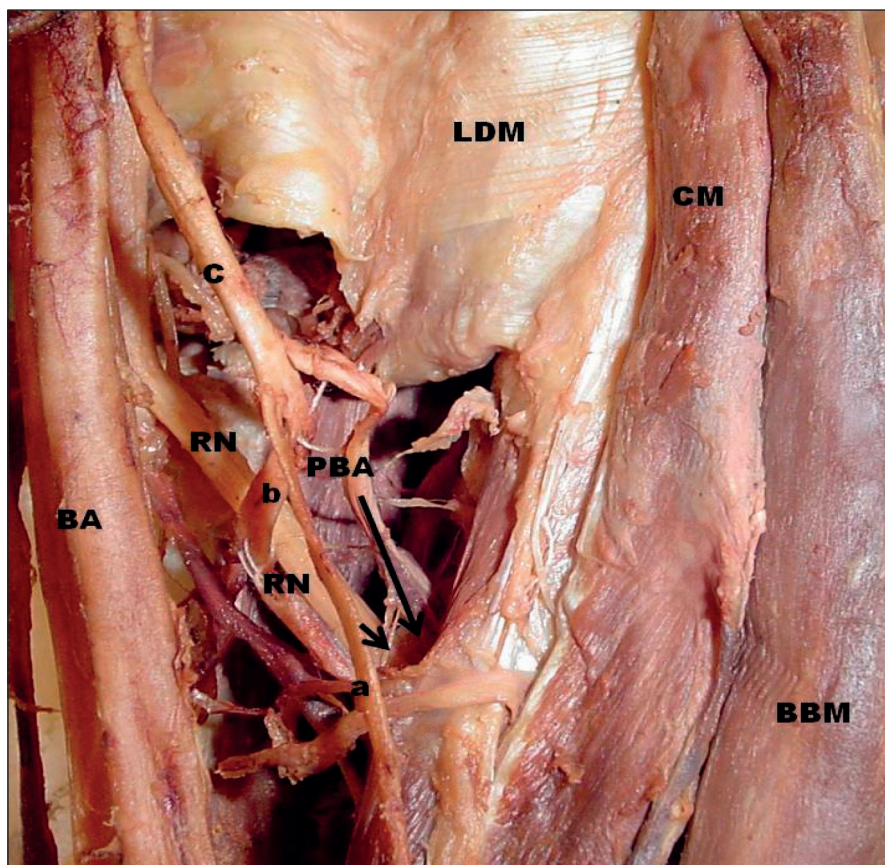
The renal arteries (RA), right and left, arise from the anterolateral aspect of abdominal aorta, at approximately the level of the superior margin of L1-L2, immediately caudal to the origin of the superior mesenteric artery. Two types of anatomical variations are reported. The first is referred as early division and characterized by branching of the main renal arteries into segmental branches proximal to the hilum. The second is known as the extra renal arterial branches, which can further divide into accessory (hilar) and aberrant (polar) arteries<sup>17-18</sup>.

Apart from the direct variations of the RA, a common and clinically important anatomical variation is the additional RA, encountered in around

30% of the human individuals (24% unilateral, 5-10% bilateral)<sup>17,19</sup>. Some studies report higher incidence up to 75.7%<sup>20</sup>. Several terms have been used for multiple renal arteries such as „accessory“, „supernumerary“, „supplementary“, „extra“, „aberrant“, „ectopic“, „plural“ and „additional“<sup>14</sup>. Our study agrees with those findings, reporting an additional RA in 20.5% of the dissected cadavers. The gradual increase in renal interventions, renal surgery, renal transplantation and therapeutic embolization, or intravascular stent placement, makes the recognition of the RA variations crucial for the successful accomplishment of various procedures<sup>17</sup>.

We have secondly investigated the arteries of the limbs, both upper and lower. The profunda brachii (PBA) artery was examined bilaterally. PBA is the largest branch of the brachial artery, which arises from the medial and posterior parts of the brachial artery just below the border of the teres major and then passes into and supplies the posterior compartment of the arm. After its entrance it passes along the radial groove on the posterior surface of the humerus deep to the lateral head of the triceps brachii muscle. Its final branches supply adjacent muscles and anastomose with the posterior circumflex humeral artery<sup>21</sup>. Most reported anatomic variations of the PBA are related to duplication of the vascular pedicle within the septum<sup>22</sup>.

The incidence of double PBA has been reported to be 4% to 12% on various studies<sup>22</sup>, origin



**Figure 2.** Common trunk of the (left) profunda brachii artery (cadaver no 23). BA: brachial artery, PBA: profunda brachii artery, RN: radial nerve, BBM: the biceps brachii muscle, CM: coracobrachialis muscle, LDM: latissimus dorsal muscle, a: muscular branch for the biceps brachii muscle, b: muscular branch for the coracobrachialis muscle, C: common trunk.

of PBA from posterior circumflex humeral (7%), origin of posterior circumflex humeral artery from PBA (16%)<sup>23</sup>. Agenesis of the brachial artery, profunda brachii artery has been noted<sup>24</sup>, while occasionally the subscapular, circumflex humeral, and profunda brachii arteries arise from a common trunk from the axillary artery (Figure 2)<sup>25-27</sup>. We report an incidence of 6.8% of a PBA having a common trunk in its origin. To recognize potential variations of the PBA is needed for possible revascularization of the flaps used for head and neck reconstruction<sup>22</sup>, and is useful during an ultrasound examination<sup>28</sup>.

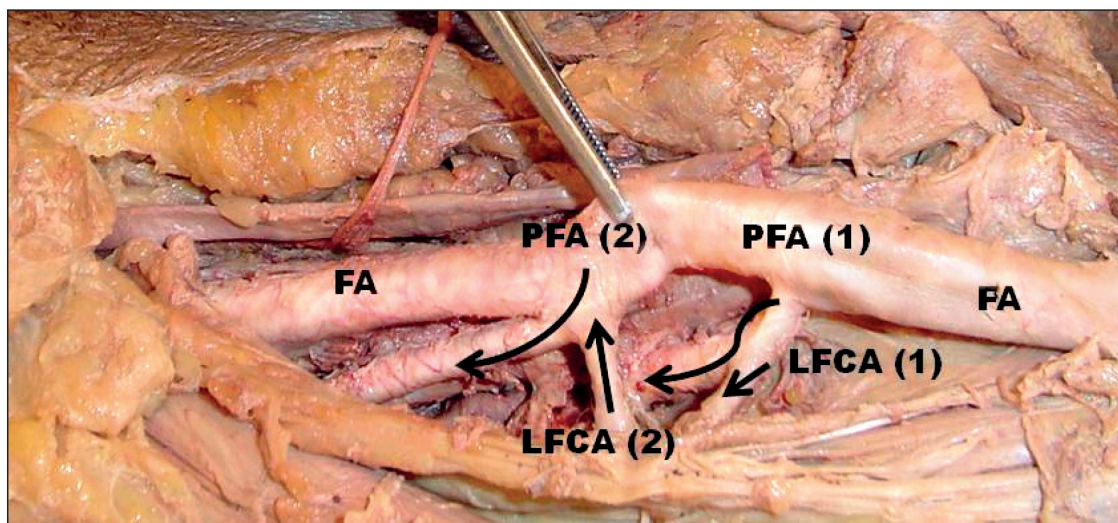
The profunda femoris artery (PFA) is the largest branch of femoral artery and the main source of blood supply to the muscles in the area of the thigh. It is given off from the lateral side of the femoral artery in the femoral triangle and passes downward and medially to the apex of the femoral triangle. Next it descends into the abductor longus<sup>29</sup>. As far as the anatomical variations of the PFA concerns, it takes off in a dorsolateral direction in about 50% of cases and it is located strictly dorsal in about 40%, a medial origin is encountered in 10% of cases, while its duplication in a medial and a lateral course is extremely rare

(Figure 3)<sup>30</sup>. However, our findings note a 2.7% of its duplication. Moreover, PFA may be rarely absent<sup>31</sup>, may present a trifurcation in 4.5% of cases and occasionally the superficial branches of femoral artery took origin from PFA instead of the femoral artery as it should<sup>32</sup>. Our study is in agreement with the international literature, reporting only a 1.4% for complete absence and no other branchial modifications. To recognize PFA variations is helpful for a series of clinical procedures like arteriography, ultrasonography and Doppler imaging and haemodialysis<sup>32</sup>, as most of the anatomical variations in the arterial pattern of the lower limb arteries cause no symptoms<sup>30</sup>.

Finally, we went over to the arteries of the neck. The brachiocephalic artery (BCA) is the first or anterior branch of the aortic arch. It arises behind the manubrium and ascends as far as the right sternoclavicular joint, there to be divided into two terminal branches, the right subclavian and right common carotid arteries<sup>33</sup>.

Anatomic variations of the BCA include tortuous brachiocephalic artery, a left brachiocephalic artery which bifurcates to form the left subclavian and common carotid arteries in 27% of the cases





**Figure 3.** Double (left) profunda femoris artery (cadaver no 30). FA: femoral artery, PFA: profunda femoris artery (1+2), LFCA: lateral femoral circumflex artery (1+2).

and absence of the BCA in 2.5% of the cases<sup>34</sup>. BCA may appear disproportionately large (steroids use, temporal arteritis, congenital)<sup>35</sup>, as in one case of our study (1.4%), in which we encountered a large BCA with a length of approximately 5.8 cm. We also note a complete absence of the BCA in a 1.4% of our dissected cadavers. Comprehension of basic angiographic anatomy of the aortic arch and the BCA is an essential component for the successful carotid artery access and the safe execution of the carotid artery stenting procedure<sup>36-37</sup>, as well as for a successful open tracheostomy<sup>38</sup>.

The vertebral artery (VA) is one of the principal arteries which supplies the brain. It is the first and largest branch of the first part of the subclavian artery, beginning in the root of the neck as a branch which arises from the super-posterior aspect of the first part of the subclavian artery. Usually, its anatomic course is divided into four segments<sup>39</sup>.

In approximately 5% of the cases the VA arises directly from the aortic arch (left VA 3.6%-5%, right VA rare approximately 0.14%), between the origin of the left common carotid and left subclavian arteries. We have encountered 6 such cases, reporting 8.2% of an origin of the left VA directly from the aortic arch, while none such case concerning the right VA was discovered. Other anatomic areas of origin are also reported in the literature<sup>40</sup>, but not met in our dissected cadavers. Rarely is reported the duplication of a VA, in agreement with our study which reports only a 1.4%. Moreover, a large VA is reported, presenting a pathological entity (large artery disease), the second most common mechanism accounting from approximately for the 32% of the cases with ischemia of the posterior cerebral circulation. This is due to

the hemodynamic bases or by occlusion of important penetrating of circumferential branches arising from the diseased vessel<sup>39</sup>. To minimize the risk of VA injury in several procedures, detailed knowledge of VA variants is crucial for both endovascular intervention and diagnostic radiology in the treatment process of patients with cerebrovascular disease<sup>40</sup>.

As a plethora of embryological malformations may occur, combined complex of vascular branching anomalies may involve different vascular districts, resulting to a combination of two or more concurrent arterial variations<sup>2,24,31,41-43</sup>. Our study reports a 12.3% for branching alternation in two different vascular districts and a 6.8% for three. Interventional practitioners should have in mind that more than one vascular variations may exist locally or at distance within the human body.

## CONCLUSION

Ignorance about arterial anatomy may have important clinical implications as well as cause a fatal misguidance in pre-procedural planning either for surgery or endovascular approach. In-depth knowledge of topographic surgical anatomy concerning deviations, variations, malformations of the circulatory system is paramount, serving as the most helpful information for radiologists, plastic surgeons and vascular surgeons<sup>44</sup>. Hence, this study may help the clinicians to avoid iatrogenic complications, as to prevent diagnostic errors, influence surgical tactics and interventional procedures and avoid complications during surgery.

**Compliance with Ethics Requirements:**

„The authors declare no conflict of interest regarding this article“

„The authors declare that all the procedures and experiments of this study respect the ethical standards in the Helsinki Declaration of 1975, as revised in 2008(5), as well as the national law. Informed consent was obtained from all the patients included in the study“

„No funding for this study“

**REFERENCES**

- Wacker FK, Lippert H, Pabst R. Arterial Variations in Humans: Key Reference for Radiologists and Surgeons. Thieme, Stuttgart, 2017.
- Lausjaunias P, Berenstein A, ter Brugge KG. Clinical Vascular Anatomy and Variations. Springer Verlag, Berlin, 2013.
- Berenstein A, Lausjaunias P. Surgical Neuroangiography. Springer Verlag, Berlin, 2012.
- Panagouli E, Venieratos D, Lolis E, Skandalakis P. Variations in the anatomy of the celiac trunk: A systematic review and clinical implications. *Annals of Anatomy* 2013;195:501-511.
- Venieratos D, Panagouli E, Lolis E, Tsaraklis A, Skandalakis P. A Morphometric study of the celiac trunk and review of the literature. *Clin Anat* 2013;26(6):741-750.
- Sürücü HS, Oto A, Gokoglu A, Celik HH, Ozdemir B, Besim A. Anatomy of the celiac trunk examined by CT imaging of 104 individuals. *Morphologie* 2003;87(277):33-35.
- Lipshutz B. A composiv study of the celiac axis artery. *Ann Surg* 1917;65:159-169.
- Michels NA. Blood supply and anatomy of the upper abdominal organs, with a descriptive atlas. Lippincot, Philadelphia, 1955.
- Higashi N, Shimada H, Simamura E, Hatta T, Branching patterns of the celiac artery as the hepato-gastro-splenic trunk. *Kaibogaku zasshi* 2009;84:7-10.
- Mburu KS, Alexander OJ, Hassan S, Bernard N. Variations in the branching pattern of the celiac trunk in a Kenyan population. *Int J Morphol* 2010;28:199-204.
- Marco-Clement I, Martinez-Barco A, Ahumada N, Simon C, Valderrama JM, Sanudo J, Arrazola J. Anatomical variations of the celiac trunk: cadaveric and radiological study. *Surg Radiol Anat* 2016;38(4):501-510.
- Iezzi R, Cotroneo AR, Giancristofaro D, Santoro M, Storto ML. Multidetector-row CT angiographic imaging of the celiac trunk: Anatomy and normal variants. *Surg Radiol Anat* 2008;30:303-310.
- Aslaner R, Pekcevik Y, Sahin H, Toka O. Variations in the origin of inferior phrenic arteries and their relationship to celiac axis variations on CT angiography. *Korean J Radiol* 2017;18(2):336-344.
- Natsis K, Paraskevas G, Panagouli E, et al. A morphometric study of multiple renal arteries in Greek population and a systematic review. *Rom J Morphol Embryol* 2014;55(3 Suppl):1111-1122.
- Singh V. Textbook of Anatomy Abdomen and Lower Limb. Elsevier Health Sciences, Faridabad, 2014.
- Chaikof EL, Cambria RP. Atlas of Vascular Surgery and Endovascular Therapy: Anatomy and Technique. Elsevier Health Sciences, Philadelphia, 2014.
- Varghese K, Adhyapak S. Therapeutic Embolization. Springer, Bangalore, 2016.
- Panagouli E, Tsaraklis A, Venieratos D. A lower polar additional renal artery in an ectopic intraperitoneal kidney. *Folia Morphol* 2011;70(1):56-58.
- Papaloucas C, Fiska A, Demetriou T. Additional renal arteries. *Clin Anat* 2007;20(4):475.
- Venieratos D, Panagouli E, Mazarakis A, Troupis T. Ipsilateral variations in the renal and vertebral arteries. *Am Surg* 2012;78(2):94-96.
- Drake R, Vogl AW, Mitchell AWM. Gray's Basic Anatomy. Elsevier Health Sciences, Philadelphia, 2016.
- Urken ML, Cheney ML, Blackwell KE, Harris JR, Hadlock TA, Futran N. Atlas of Regional and Free Flaps for Head and Neck Reconstruction: Flap Harvest and Insetting. Lippincott Williams & Wilkins, Philadelphia, 2012.
- Platzer W, Ronan O'Rahilly R. Atlas of topographical anatomy. G. Thieme Verlag, Berlin, 1985.
- Doyle JR. Surgical Anatomy of the Hand and Upper Extremity. Lippincott Williams & Wilkins, Philadelphia, 2003.
- Mauro MA, Murphy KPJ, Thomson KR, Venbrux AC, Morgan RA. Image-Guided Interventions: Expert Radiology Series. Elsevier Health Sciences, Philadelphia, 2013.
- Aastha, Jain A, Kumar MS. An unusual variation of axillary artery: a case report. *J Clin Diagn Res* 2015;9(1):AD05-7.
- Naveen K, Jyothsna P, Nayak SB, et al. Variant origin of an arterial trunk from axillary artery continuing as profunda brachii artery-a unique arterial variation in the axilla and its clinical implications. *Ethiop J Health Sci* 2014;24(1):93-6.
- Hutchison SJ, Holmes KC. Principles of Vascular and Intravascular Ultrasound. Elsevier Health Sciences, Philadelphia, 2011.
- Halim A. Human Anatomy, Abdomen And Lower Limb. I. K. International Pvt Ltd, New Delhi, 2008.
- Heberer G, van Dongen RJAM. Vascular surgery. Springer Science & Business Media, Berlin, 2012.
- Tubbs RS, Shoja MM, Loukas M. Bergman's Comprehensive Encyclopaedia of Human Anatomic Variation. John Wiley & Sons, Hoboken, 2016.
- Rajani SJ, Ravat MK, Rajani JK, Bhedi AN. Cadaveric study of profunda femoris artery with some unique variations. *J Clin Diagn Res* 2015;9(5):AC01-3.
- Abrahams PH, Craven JL, Lumley JSP. Illustrated Clinical Anatomy, Second Edition. CRC Press, London, 2011.
- Moore KL, Dalley AF, Agur AMR. Clinically Oriented Anatomy. Lippincott Williams & Wilkins, Philadelphia, 2013.
- White RA, MD, Hollier LH. Vascular Surgery: Basic Science and Clinical Correlations. John Wiley & Sons, Malden, 2008.
- Vučurević G, Marinković S, Puškaš L, Kovačević I, Tanasković S, Radak D, Ilić A. Anatomy and radiology of the variations of aortic arch branches in 1,266 patients. *Folia Morphol (Warsz)* 2013;72(2):113-22.
- Al-Mubarak N. Carotid Artery Stenting: Current Practice and Techniques. Lippincott Williams & Wilkins, Philadelphia, 2004.
- Huempferner-Hierl H, Hierl T, Halama D. Rare anatomical variation of the brachiocephalic trunk encountered in tracheostomy. *Br J Oral Maxillofac Surg* 2017;55(3):312-313.
- Casserly IP, Sachar R, Yadav JS. Manual of Peripheral Vascular Intervention. Lippincott Williams & Wilkins, Philadelphia, 2005.

40. Lazaridis N, Piagkou M, Loukas M, et al. A systematic classification of the vertebral artery variable origin: clinical and surgical implications. *Surg Radiol Anat* 2018. doi: 10.1007/s00276-018-1987-3.
41. Grabherr S, Grimm JM, Heinemann A. Atlas of Postmortem Angiography. Springer, New York, 2016.
42. Panagouli E, Tsaraklis A, Gazouli I, Anagnostopoulou S, Venieratos D. A rare variation of the axillary artery combined contralaterally with an unusual high origin of a superficial ulnar artery: description, review of the literature and embryological analysis. *Ital J Anat Embryol* 2009;114(4):145-56.
43. Troupis TG, Michalinos A, Vlastos D, et al. Combined variations of superior mesenteric artery branches. *Am Surg* 2014;80(4):E103-4.
44. Tsoucalas G. Anatomy: an essential course for future surgeons. *J Universal Surg* 2018;6(1):8.