

# SURGICAL TREATMENT OF MILD TO MODERATE HALLUX VALGUS

Dmytro V. PROZOROVSKIY<sup>1</sup>, Ruslan I. BUZNYTSKIY<sup>2</sup>✉

<sup>1</sup> Department of traumatology and orthopedics, Sytenko Institute of Spine and Joint Pathology NAMS of Ukraine

<sup>2</sup> Department of traumatology and orthopedics, Kharkiv Medical Academy of Postgraduate Education, Ukraine

Received 25 Jan 2019, Accepted 04 Apr 2019

<https://doi.org/10.31688/ABMU.2019.54.2.11>

## ABSTRACT

**Introduction.** Recently, an increasing number of publications addressed the treatment of mild and moderate hallux valgus using corrective diaphyseal and distal osteotomies of the first metatarsal bone. Most of the diaphyseal and distal osteotomies of the first metatarsal bone are fixed with screws, which in combination with the shape of the bone saw cut provide, according to the authors, stability that is sufficient for early mobilization of patients, namely walking.

**The objective of the study** is a comparative analysis of the results of surgical treatment of patients with mild and moderate hallux valgus with the use of corrective proximal sphenoid osteotomy of the first metatarsal bone and Scarf osteotomy.

**Materials and methods.** The study is based on the surgical treatment of 100 patients with transverse-spread deformity of the forefoot and valgus deformation of the great toe of mild and moderate severity. Patients were divided into two groups, equal in number of people, gender (all women) and the average severity of the forefoot deformity. Patients of group 1 underwent corrective proximal sphenoid osteotomy (closing wedge) of the first metatarsal bone with

## RÉSUMÉ

**Le traitement chirurgical de l'hallux valgus léger au modéré**

**Introduction.** Récemment, une augmentation de l'incidence de hallux valgus légère et modérée utilisant des ostéotomies diaphysaires et distales correctives du premier os métatarsien a été observée. La plupart des ostéotomies diaphysaires et distales du premier os métatarsien sont fixées à l'aide de vis qui, combinées avec la forme de l'os, suffisent selon les auteurs pour la mobilisation précoce des patients, notamment la marche.

**L'objectif de l'étude** est l'analyse comparative des résultats du traitement chirurgical des patients atteints de hallux valgus légers et modérés avec l'utilisation d'une ostéotomie rectale proximale du sphénoïde du premier métatarsien et d'une ostéotomie de Scarf.

**Matériels et méthodes.** L'étude porte sur 100 patients présentant une déformation transverse de l'avant-pied et une déformation en valgus du gros orteil d'intensité légère et modérée. Les patients ont été divisés en deux groupes: nombre égal de personnes, sexe (100 femmes) et gravité moyenne de la déformation de l'avant-pied. Les patients du groupe 1 ayant subi une

✉ Address for correspondence:

Ruslan I. BUZNYTSKIY  
Department of Traumatology and Orthopedics, Kharkiv Medical Academy of Postgraduate Education, Ukraine  
Address: Amosova Street, 52, 133, Kharkiv, Ukraine 61176  
E-mail: ruslan3buz@gmail.com; Phone: +380506056230

fixation of “T”-shaped plate LCP of a single manufacturer. Patients of the group 2 underwent corrective Scarf osteotomy of the first metatarsal bone with fixation by two screws of a single manufacturer.

**Results.** The average score of the treatment result according to the Groulier scale in group 1 is higher ( $76.40 \pm 0.83$  points) than in group 2 ( $70.88 \pm 1.45$  points) ( $t$  3.3;  $p < 0.001$ ). Among the complications after surgical treatment of transverse-spread deformation of the feet, the most common was recurrence of hallux valgus, reaching 28 % of cases in group 2, which is 22% higher than in group 1.

**Conclusions.** Displacement of the bone fragments of the first metatarsal bone in the osteotomy zone in the period of rehabilitation of the patients of group 2 resulted in 28% of cases of hallux valgus recurrence in the distant postoperative period, which is 22% higher than that in patients of group 1.

**Keywords** hallux valgus, treatment, Scarf osteotomy, closing wedge osteotomy.

#### **Abbreviations list:**

M1/M2 – the angle between the axes of the first and second metatarsal bones; M1/P1 – the angle of valgus deviation of the great toe; PASA – Proximal Articular Set Angle; HFMB – head of the first metatarsal bone; pre-op – before operation, post-op – after operation.

## **INTRODUCTION**

Transverse-spread deformation of the anterior part of the feet with hallux valgus reaches 75% of the prevalence among females<sup>1,2</sup>. Pain on the tops of foot deformities during walking, difficulties in choosing shoes and cosmetic defect accompanying this disease significantly reduce the quality of life, and the high frequency of the disease in young and middle-aged women increases the relevance of the existing problem<sup>3,4</sup>.

The etiology and pathogenesis of the disease are complex and multifactorial and require further research<sup>2,5</sup>. However, it is known that the main in the formation of hallux valgus is the multi-plane deformation of the first metatarsal bone, mainly its varus deviation<sup>3,6</sup>.

Recently, there has been a tendency to increase the number of publications devoted to the treatment of mild and moderate hallux valgus using corrective diaphyseal (Scarf, Mau) and distal (Chevron, Mitchell) osteotomies of the first metatarsal bone<sup>3,7,9</sup>. Each of the variants of osteotomy has certain possibilities in terms of correction of the components of the first metatarsal bone deformation, which is due to

correction ont subi une ostéotomie sphénoïdale proximale du premier os métatarsien avec une fixation du LCP en forme de «T» d'un seul fabricant. Les patients du groupe 2 ont subi une ostéotomie correctrice du premier os métatarsien avec fixation de deux vis d'un même fabricant.

**Résultats.** Le score moyen de l'échelle de Groulier dans le groupe 1 est plus élevé ( $76,40 \pm 0,83$  points) que dans le groupe 2 ( $70,88 \pm 1,45$  points) ( $t$  3,3,  $p < 0,001$ ). Parmi les complications après traitement chirurgical d'une déformation transversale des pieds, la plus fréquente était la récurrence de hallux valgus, atteignant 28% des cas dans le groupe 2, ce qui est 22% plus élevé que dans le groupe 1.

**Conclusions.** Il a été noté dans le second group une récurrence de 28% de hallux valgus après un déplacement des fragments d'os du premier métatarsien lors de la période en post-opératoire, soit 22% de plus que dans le premier group

**Mots-clés:** hallux valgus, traitement, ostéotomie Scarf, ostéotomie en coin.

the localization of osteotomy, its shape and the need to preserve the contact of bone fragments for the fusion of the osteotomy zone.

It should be noted that most of the diaphyseal and distal osteotomies of the first metatarsal bone are fixed with screws, which in combination with the shape of the bone saw cut provide, according to the authors, stability that is sufficient for early mobilization of patients, namely walking<sup>10-12</sup>.

**THE OBJECTIVE OF THE STUDY** was a comparative analysis of the results of surgical treatment of patients with mild and moderate hallux valgus, with the use of corrective proximal sphenoid osteotomy of the first metatarsal bone and Scarf osteotomy.

## **MATERIALS AND METHODS**

The study is based on the surgical treatment of 100 patients with transverse-spread deformity of the forefoot and valgus deformation of the great toe of mild and moderate severity. Surgical treatment was performed at the Sytenko Institute of Spine and Joint Pathology NAMS of Ukraine.

Patients underwent standard clinical and radiographic examinations: the angle between the axes of the first and second metatarsal bones (M1/M2), the angle of valgus deviation of the great toe (M1/P1), the angle of inclination of the articular surface of the head of the first metatarsal bone (Proximal Articular Set Angle - PASA). The degree of severity was determined according to the classification of R.A. Mann<sup>13</sup>. All patients lacked clinical signs of hypermobility of the first tarsometatarsal joint<sup>14</sup>.

Patients were divided into two groups, equal in number of people, gender (all women) and the average severity of the forefoot deformity, which is confirmed statistically (Table 1). The mean age of group 1 patients was  $36.6 \pm 1.46$  years and in group 2 it was  $33.14 \pm 1.45$  years ( $t$  1.4,  $p > 0.05$ ). The average follow-up period of group 1 patients reached  $29.90 \pm 1.26$  months and in group 2 it was  $28.00 \pm 0.99$  months ( $t$  1.2,  $p > 0.05$ ).

Patients of group 1 underwent corrective proximal sphenoid osteotomy (closing wedge) of the first metatarsal bone with fixation of "T"-shaped plate LCP of a single manufacturer. Patients of the 2 group underwent corrective Scarf osteotomy of the first metatarsal bone with fixation by two screws of a single manufacturer. In all cases, patients in groups 1 and 2 underwent the Schede operation, release of the lateral capsule of the first metatarsophalangeal joint with cutting the tendons of the transverse belly of m. adductor hallucis from the proximal phalanx of the great toe and medial capsulorrhaphy.

On the second day after surgery and up to 1.5-2.0 months, patients were allowed to walk in special shoes Barouk which are unloading the forefeet. In most cases, full load on the foot was allowed 2 months after the operation, after the control x-ray examination.

Clinical evaluation of the treatment results was performed using the Groulier score scale<sup>15</sup>.

The information array was processed statistically. The Shapiro-Wilk method (Shapiro-Wilk W tests) was used to test the hypothesis of the normal distribution of the selection. Comparison of the data of x-ray examination of patients of two groups before and after surgical treatment was carried out using T-test.

## RESULTS

According to Groulier score scale, the result of treatment among patients of group 1 in 31 (62.0%) cases is regarded as excellent, in 16 (32.0%) cases - good and in 3 (6.0%) cases - satisfactory.

In the second group, an excellent result of treatment was achieved in 27 (54.0%) cases, a good result in 11 (20.0%) cases, and a satisfactory one in 12 (24.0%) cases. In both groups there were no unsatisfactory results of treatment.

The average score of the treatment result according to the Groulier scale in group 1 is higher ( $76.40 \pm 0.83$  points) than in group 2 ( $70.88 \pm 1.45$  points) ( $t$  3.3,  $p < 0.001$ ) (Table 2).

**Table 1.** The dynamics of radiographic parameters in patients with hallux valgus 1 and 2 groups before and after surgical treatment (M $\pm$ m)

Patients	Angle M1/M2 (°)			Angle M1/P1 (°)			PASA (°)		
	pre-op	post-op	follow-up	pre-op	post-op	follow-up	pre-op	post-op	follow-up
Group 1, n=50	14.02 $\pm$ 0.21	7.86 $\pm$ 0.15	8.26 $\pm$ 0.18	31.66 $\pm$ 0.61	9.98 $\pm$ 0.39	12.32 $\pm$ 0.43	11.08 $\pm$ 0.58	12.00 $\pm$ 0.71	12.20 $\pm$ 0.63
Group 2, n=50	13.78 $\pm$ 0.22	8.70 $\pm$ 0.17	10.02 $\pm$ 0.37	31.42 $\pm$ 0.63	11.82 $\pm$ 0.59	18.26 $\pm$ 0.96	10.92 $\pm$ 0.68	11.22 $\pm$ 0.69	10.28 $\pm$ 0.65
t; p	t 0.78 p> 0.05	t 3.7 p< 0.001	t 4.3 p< 0.001	t 0.27 p> 0.05	t 2.6 p< 0.01	t 5.7 p< 0.001	t 0.18 p> 0.05	t 0.79 p> 0.05	t 2.1 p< 0.05

Note: after operation (post-op), before operation (pre-op) and further in the text

**Table 2.** The results of treatment of patients with hallux valgus 1 and 2 groups according to the Groulier score scale (M $\pm$ m)

Patients	pre-op	follow-up
Group 1, n=50	48.12 $\pm$ 0.68 points	76.40 $\pm$ 0.83 points
Group 2, n=50	48.58 $\pm$ 0.60 points	70.88 $\pm$ 1.45 points
t; p	t 0.51 p>0.05	t 3.3 p<0.001

**Table 3.** Complications in patients with hallux valgus 1 and 2 groups after surgical treatment.

Patients	Recurrence of hallux valgus	Hallux varus	Aseptic necrosis of HFMB	Non-fusion of the osteotomy zone	Metatarsalgia
Group 1, n=50	3 (6%)	1 (2%)	-	-	1 (2 %)
Group 2, n=50	14 (28 %)	-	-	-	1 (2 %)

Note: head of the first metatarsal bone (HFMB)

When comparing the value of correction of varus deformation of the first metatarsal bone and valgus deformation of the great toe in patients of groups 1 and 2 after surgery, a mild advantage in the use of proximal sphenoid osteotomy of the first metatarsal bone is determined (Table 1). Along with this, in the postoperative period in group 2 the loss of the average value of the correction of both, the angle M1/M2 ( $10.02^{\circ} \pm 0.37^{\circ}$ ) and the angle M1/P1 ( $18.26^{\circ} \pm 0.96^{\circ}$ ), was noted, which is explained by 14 (28%) cases of displacement of bone fragments of the first metatarsal bone in the osteotomy area by the value equal, in most cases, to the initial deformation. These cases were registered at the stage of control radiographs 1.5 months after the operation (Table 3). At the same time, in patients of group 1 in the distant postoperative period, the correction of the forefoot deformity remains and the average angle M1/M2 and M1/P1 is  $8.26^{\circ} \pm 0.18^{\circ}$  and  $12.32^{\circ} \pm 0.43^{\circ}$ , respectively.

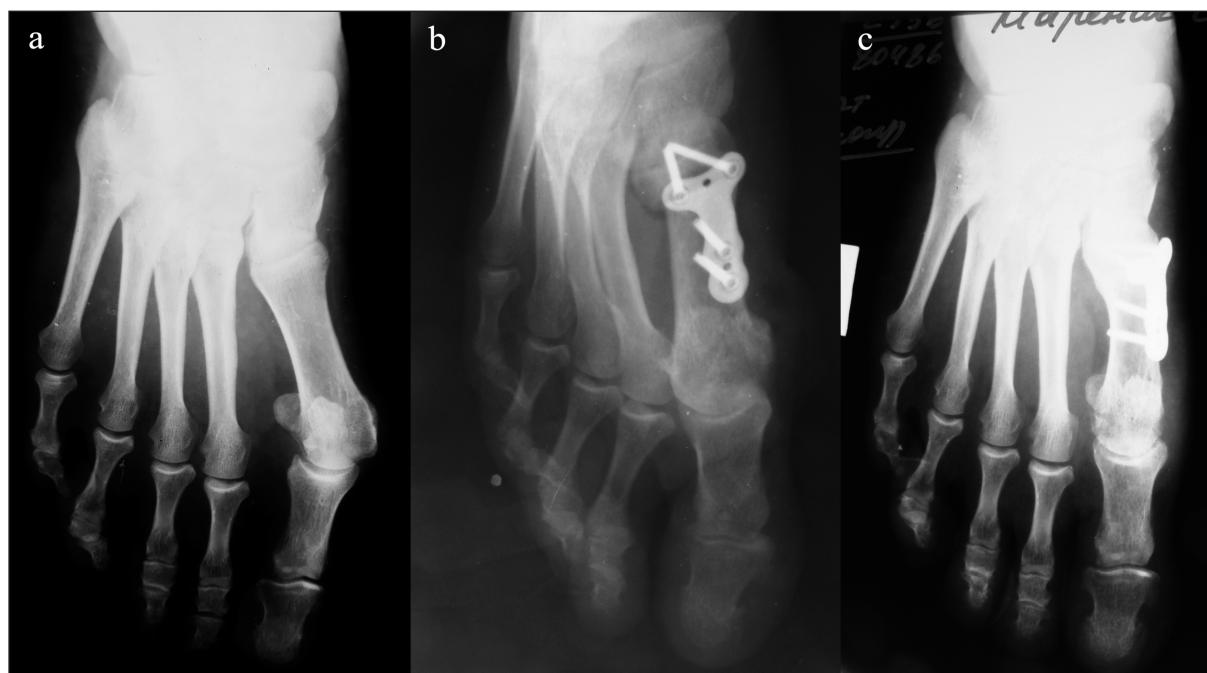
There were no significant differences in the mean values of PASA angle changes in patients of groups

1 and 2 before and after surgery (Table 1). Among the complications after surgical treatment of transverse-spread deformation of the feet, the most common was recurrence of hallux valgus, reaching 28% of cases in group 2, which is 22% higher than in group 1 (Table 3). Both in group 1 and in group 2 in the distant postoperative period metatarsalgia was registered in 1 (2 %) case (Table 3). In group 1 there was 1 (2 %) case of varus deformation of the great toe (Table 3).

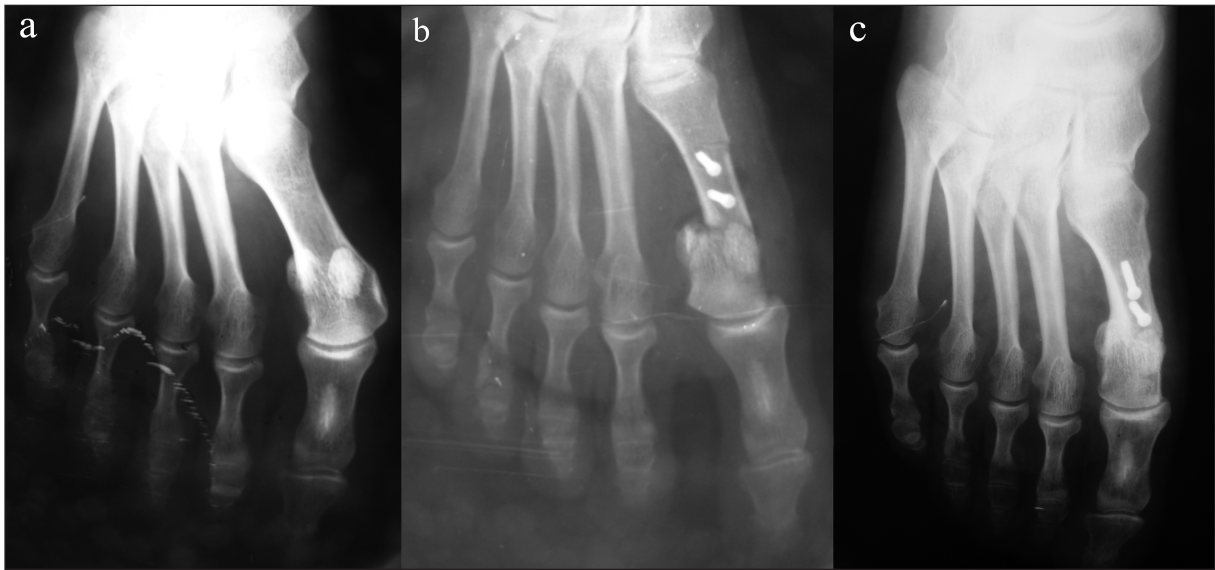
In both groups, the fusion of osteotomy zones of the first metatarsal bone was achieved in 100 % of cases (Table 3).

**Clinical example no 1.**

Patient, 39 years old, diagnosis: right foot moderate hallux valgus. Score according to the Groulier scale – 51 points. X-ray: angle M1/M2-16°, M1/P1 – 32°, PASA – 16° (Fig. 1 a). The patient underwent surgery: Shede operation, lateral release, corrective proximal sphenoid osteotomy of the first metatarsal bone, fixation by LCP plate on the right foot (Fig. 1 b).



**Fig. 1.** X-ray of the right foot of the patient, 39 years old, anterior-posterior view: a – before surgery, b – intraoperatively; c – 4 years after surgery.



**Fig. 2.** X-ray of the right foot of the patient, 27 years old, anterior-posterior view:  
a – before surgery, b – intraoperatively; c – 3 years after surgery.

The result of treatment 4 years after surgery is excellent on the scale of Groulier (85 points). The correction of the deformity of the anterior right foot according to X-ray remains: angle M1/M2-4°, M1/P1-6°, PASA-8° (Fig. 1 C).

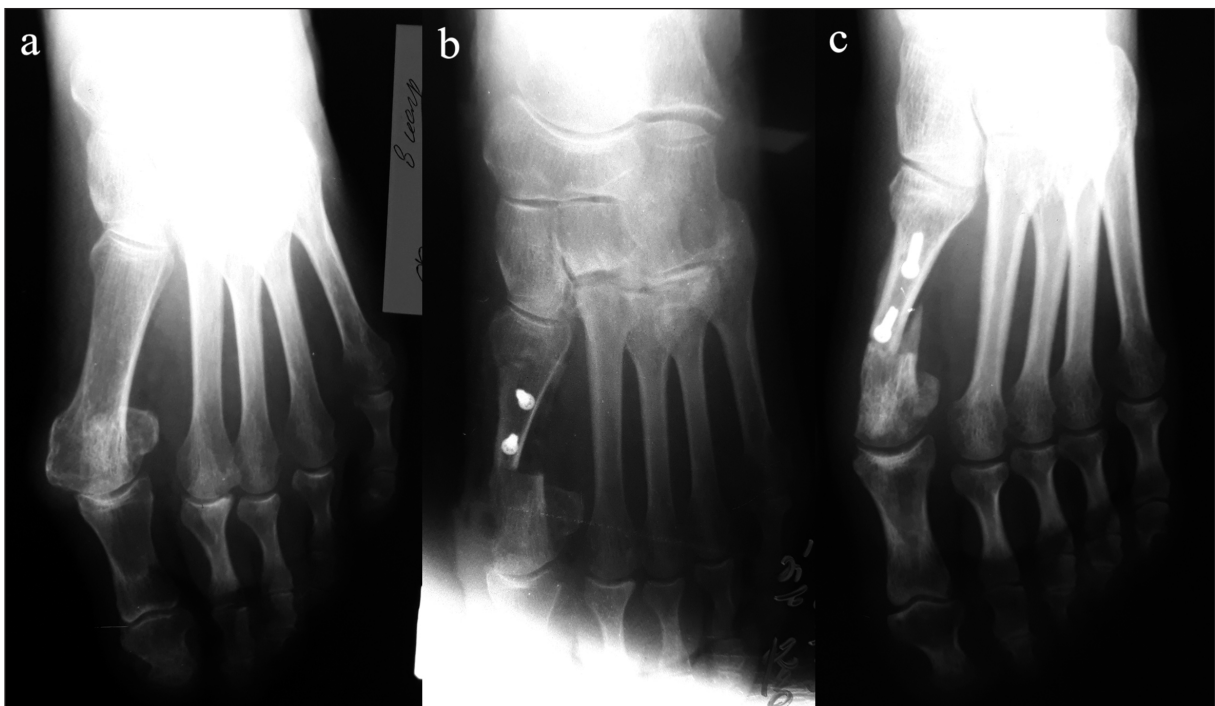
**Clinical example no 2.**

Patient, 27 years old, diagnosis: right foot moderate hallux valgus. Score according to the Groulier

scale – 59 points. X-ray: angle M1/M2- 13°, M1/P1 – 34°, PASA – 17° (Fig. 2 a).

The patient underwent surgery: Shede operation, lateral release, corrective Scarf osteotomy of the first metatarsal bone, fixation with two screws on the right foot (Fig. 2 b).

The result of treatment 3 years after surgery is regarded as excellent, according to the scale of Groulier (81 points). The correction of the deformity of the



**Fig. 3.** X-ray of the left foot of the patient, age 66, anterior-posterior view:  
a – before surgery, b – intraoperatively; c – 1.5 months after operation.

anterior right foot according to x-ray remains: angle M1/M2-5°, M1/P1-11°, PASA-10° (Fig. 2 C).

### Clinical example no 3.

Patient, 66 years old, diagnosis: left foot moderate hallux valgus. Score on the scale of Groulier – 55 points. X-ray: angle M1/M2 – 13°, M1/P1 – 30°, PASA – 17°. (Fig. 3 a).

The patient underwent surgery: Shede operation, lateral release, corrective Scarf osteotomy of the first metatarsal bone, fixation with two screws on the left foot (Fig. 3 b).

On control radiographs 1.5 months after the operation, the loss of correction of varus deformation of the first metatarsal bone by the value equal to the initial deformation as a result of displacement of bone fragments in the osteotomy zone was determined (Fig. 3 C). In this regard, in the distant postoperative period there was a recurrence of hallux valgus.

### DISCUSSION

Recently, the use of scarf osteotomy for the treatment of mild to moderate hallux valgus has increased<sup>3,11,16</sup>. This osteotomy, in comparison with proximal wedge-shaped osteotomy (closing wedge), allows to maintain the length of the first metatarsal bone or to perform its elongation, but has limitations in the value of correction of varus deformation of the first metatarsal bone<sup>3,17</sup>.

Young et al<sup>17</sup>, on the basis of treatment of 44 hallux valgus cases, assert high stability of fixation with screws after scarf osteotomy and report only 3 (6.8%) cases of recurrent deformation, the average angle M1/M2 improved from 14.3° to 8.6°, the angle M1/P1 – from 32.2° to 12.5°. Adam et al<sup>18</sup> present the results of treatment of 34 cases, in whom M1/M2 angle index improved from 15.8° to 7.2°, M1/P1 angle – from 34.6° to 14.9°. Fuhrmann et al<sup>19</sup> report interim results of treatment of 144 cases of hallux valgus using the Scarf osteotomy, in whom the angle of M1/M2 improved from 13.8° to 10.7°, the angle M1/P1 – 39.0° to 24.8°. Murawski et al<sup>20</sup>, in their study of 140 cases of hallux valgus treatment, show excellent treatment results, improvement of M1/M2 angle from 18.0° to 8.0°, M1/P1 angle from 37.0° to 12.0°.

Thus, the literature data are scattered, some studies are comparable with the data obtained by us. Taking into account the complications after surgical treatment of mild to moderate hallux valgus when using Scarf osteotomy, proximal wedge-shaped osteotomy (closing wedge) of the first metatarsal bone with plate fixation may be the method of choice in the treatment of such patients.

### CONCLUSIONS

The use of both proximal sphenoid osteotomy of the first metatarsal bone and Scarf osteotomy in the surgical treatment of mild and moderate hallux valgus allows to completely correct the deformation during the operation.

Displacement of the bone fragments of the first metatarsal bone in the osteotomy zone in the period of rehabilitation of the patients of group 2 resulted in 28% of cases of hallux valgus recurrence in the distant postoperative period, which is 22% higher than that in patients of group 1.

Surgical treatment of patients with mild and moderate hallux valgus with the help of corrective proximal sphenoid osteotomy (closing wedge) of the first metatarsal bone with fixation with “T”-shaped plate LCP allows to obtain excellent and good results in 94% of cases.

### Compliance with Ethics Requirements:

„The authors declare no conflict of interest regarding this article“

„The authors declare that all the procedures and experiments of this study respect the ethical standards in the Helsinki Declaration of 1975, as revised in 2008(5), as well as the national law. Informed consent was obtained from all the patients included in the study“

„No funding for this study“

### REFERENCES

1. Kondrashova IA, Davletova NA, Kondrashov AN. Clinoradiological aspects for diagnosis of hallux valgus and metatarsus latus (Published in Ukrainian). *Trauma*. 2013;14(4):81-86.
2. Nix S, Smith M, Vicenzino B. Prevalence of hallux valgus in the general population: a systematic review and meta-analysis. *Journal of Foot and Ankle Research*. 2010;21(3):21.
3. Prozorovsky DV, Romanenko KK, Yershov DV. Scarf osteotomy in the treatment of hallux valgus (Published in Ukrainian). *Trauma*. 2013;14(2):132-136.
4. Jezussek D, Hönle W, Schuh A. Clinical signs and diagnosis of hallux valgus. *MMW – Fortschritte der Medizin*. 2006;148(48):33-34, 36.
5. Mortier JP, Bernard JL, Maestro M. Axial rotation of the first metatarsal head in a normal population and hallux valgus patients. *Orthopaedics & Traumatology, Surgery & Research*. 2012;98(6):677-683.
6. Perera AM, Mason L, Stephens MM. Current concepts review: the pathogenesis of hallux valgus. *Journal of Bone & Joint Surgery*. 2011;93(17):1650-1661.
7. Groningen B, Steen MC, Reijman M, et al. Outcomes in chevron osteotomy for hallux valgus in a large cohort. *Foot (Edinburgh, Scotland)*. 2016;29:18-24.
8. Nabi G, Ahsan M, Bashir N, Islam N. Clinical results of Mitchell's osteotomy for treatment of

- hallux valgus. *International Journal of Orthopaedics Sciences*. 2017;3(2):741-744.
9. Yunus T. Chevron osteotomy with Herbert Screw fixation for treatment of hallux valgus deformity results. *Süleyman Demirel Üniversitesi Tıp Fakültesi Dergisi*. 2017;24(3):75-83.
  10. Doğar F, Ozan F, Gürbüz K, et al. Distal metatarsal osteotomy in hallux valgus surgery: Chevron osteotomy. *Journal of Clinical and Analytical Medicine*. 2015;6 (suppl 6):752-755.
  11. Law KW, Alwin HY, Li PH. Scarf osteotomy in treating hallux valgus: clinical and radiographical outcome and technical notes. *Journal of Orthopedics, Trauma and Rehabilitation*. 2014;18(1):22-26.
  12. Ünal AM, Baran Ö, Uzun B, Turan AC. Comparison of screw-fixation stabilities of first metatarsal shaft osteotomies: a biomechanical study. *Acta Orthopaedica et Traumatologica Turcica*. 2010;44(1):70-75.
  13. Mann RA, Coughlin MJ. Adult hallux valgus, in "Surgery of the foot and ankle", vol.1, 7th ed, MJ Coughlin, RA Mann (eds). St. Louis, Mosby, 1999:150-269.
  14. Faber FM, Mulder PH, Verhaar JN. Role of first ray hypermobility in the outcome of the hohmann and the lapidus procedure: a prospective, randomized trial involving one hundred and one feet. *The Journal of Bone & Joint Surgery*. 2004;86-A(3):486-495.
  15. Groulier P, Curvale G, Prudent HP, et al. Resultats du traitement de l'hallux valgus selon la technique de Mac Bride "modifiée" avec ou sans osteotomie phalangienne ou metatarsienne complementaire. *Revue de Chirurgie Orthopédique et Réparatrice de l'Appareil Moteur*. 1988;74:539-548.
  16. Giannini S, Cavallo M, Faldini C, et al. The SERI distal metatarsal osteotomy and Scarf osteotomy provide similar correction of hallux valgus. *Clinical Orthopedics and Related Research*. 2013;471(7):2305-2311.
  17. Young KW, Lee HS, Park SC. Modified proximal Scarf osteotomy for hallux valgus. *Clinics in Orthopedic Surgery*. 2018;10:479-483.
  18. Adam SP, Choung SC, Gu Y, O'Malley MJ. Outcomes after scarf osteotomy for treatment of adult hallux valgus deformity. *Clinical Orthopaedics and Related Research*. 2011;469(3):854-859.
  19. Fuhrmann RA, Zollinger-Kies H, Kundert HP. Mid-term results of Scarf osteotomy in hallux valgus. *International Orthopaedics*. 2010;34(7):981-989.
  20. Murawski CD, Egan CJ, Kennedy JG. A rotational scarf osteotomy decreases troughing when treating hallux valgus. *Clinical Orthopedics and Related Research*. 2011;469(3):847-853.