

## CASE REPORT

# TWO CLINICAL CASES OF MODERN POSTOPERATIVE TREATMENT OF A 3<sup>RD</sup> DEGREE SKIN BURN WITH THERESIENÖL

Strahil A. STRASHILOV<sup>1</sup>✉, Angel D. YORDANOV<sup>2</sup>, Polina P. VASILEVA<sup>3</sup>

<sup>1</sup> Department of Plastic Restorative, Reconstructive and Aesthetic Surgery, University Hospital „Dr. Georgi Stranski“, Medical University Pleven, Bulgaria

<sup>2</sup> Clinic of Gynecologic Oncology, University Hospital „Dr. Georgi Stranski“, Medical University Pleven, Bulgaria

<sup>3</sup> Department of Obstetrics and Gynecology, Medical University Pleven, Bulgaria

Received 05 June 2019, Accepted 24 July 2019

<https://doi.org/10.31688/ABMU.2019.54.3.28>

### ABSTRACT

**Introduction.** Skin burns are one of the most common traumatic injuries in human society. Most of them are small in area and not life-threatening, due to which people hardly look for specialized medical care for their treatment. This is not the case with large burns, which even of a low grade may result in serious complications and even death. According to the injury depth the burns are divided into 1<sup>st</sup>, 2<sup>nd</sup>, 3<sup>rd</sup> and 4<sup>th</sup> degree, while the most frequently used method to define their area relative to the total body surface is that of the nines. The treatment of burns is a difficult and slow process and is directly depending on their depth, area and injuring agent. Surgical and non-surgical method are used, their goal being the following: pain reduction, prevention of infection, removal of avital tissues, preventing the formation of coarse scars, keloids and contractures of the joints or if the patient has them, they to be as minimal as possible and finally overcoming the consequences.

### RÉSUMÉ

**Deux cas cliniques de traitement post-opératoire moderne des brûlures de la peau de troisième degré avec du Thérésienöl**

**Introduction.** Les brûlures de la peau sont l'une des lésions traumatiques les plus courantes dans la société humaine. La plupart d'entre elles sont de petite taille et ne mettent pas la vie en danger, de sorte que les gens ne recherchent guère de soins médicaux spécialisés pour leur traitement. Ce n'est pas le cas des grandes brûlures qui, même de faible intensité, peuvent entraîner des complications graves, voire la mort. En fonction de la profondeur de la blessure, les brûlures sont divisées en degrés I, II, III et IV. La méthode la plus fréquemment utilisée pour définir leur surface par rapport à la surface totale du corps est celle des neuf. Le traitement des brûlures est un processus lent et difficile qui dépend directement de la profondeur, de la zone et de l'agent blessant. Des méthodes chirurgicales et

✉ Address for correspondence:

Strahil A. STRASHILOV  
Department of Plastic Restorative, Reconstructive and Aesthetic Surgery,  
Medical University Pleven, Bulgaria  
Address: Bul. Georgi Kochev 8A, Pleven, P.C. 5800, Bulgaria  
E-mail: dr.strashilov@gmail.com; Phone: 00359 887 242 163; Fax: 00359  
64 886 237

**Cases presentation.** We present here two clinical cases of 3<sup>rd</sup> degree limited burns, initially treated with necrectomy and antiseptic silver dressings, and subsequently alternatively with Theresienöl.

**Conclusions.** Theresienöl is a good alternative to the free skin graft plastics, when it refers to 3<sup>rd</sup> degree, small size burns.

**Keywords:** Theresienöl, skin burn, 3<sup>rd</sup> degree skin burn.

## INTRODUCTION

Skin burns are one of the most common traumatic injuries in humans. Most of them are small in area and not life-threatening, due to which people hardly look for specialized medical care for their treatment. This is not the case with large burns, which even of a low grade may result in serious complications and even death<sup>1</sup>. According to their aetiology, the burns are divided into: scalding (result from hot fluids), flame-type (resulting from fire), contact (resulting from contact with hot objects), electrical (result from electric current), radiational (resulting from impact of radiational substances), chemical (resulting from the impact of chemical substances)<sup>1-6</sup>.

According to the injury depth, the burns are classified into:

- 1<sup>st</sup> degree – the epidermis is intact, the skin is tender, red, dry and with no blisters;
- 2<sup>nd</sup> degree – partial damage of skin layers:
  - 2 A – superficial partial damage: here the epidermis is destroyed; there are skin blisters, while the underlying derma is wet, pink and very tender and painful. When compressed, it gets pale and after that the capillary filling is immediate.
  - 2 B – deep partial damage: the epidermis and the superficial derma are destroyed and the deep derma is observed. The diagnosis of this type is difficult, because the damaged area may look like 2 A or 3<sup>rd</sup> degree, but in all cases after compression the capillary filling is either lacking or very slow.
- 3<sup>rd</sup> degree – total destruction of the epidermis and the derma, there is no pain, due to killing the nerve endings, while the skin is white to dark

non-chirurgicales sont utilisées, leurs objectifs étant les suivants: réduction de la douleur, prévention des infections, enlèvement des tissus avitaux, prévention de la formation de cicatrices grossières, de chéloïdes et de contractures aux articulations ou, si le patient les a, qu'elles soient minimales et finalement aux conséquences surmontables.

**Rapport du cas.** Nous présentons ici deux cas cliniques de brûlures limitées au III<sup>e</sup> degré, initialement traitées par une nécréctomie et des pansements antiseptiques à l'argent et par la suite avec Theresienöl.

**Conclusions.** Theresienöl est une bonne alternative aux plastiques greffés à peau libre, lorsqu'il s'agit de brûlures de petite taille de III<sup>e</sup> degré.

**Mots-clés:** Theresienöl, brûlures cutanées, brûlures cutanées de III<sup>e</sup> degré.

brown, depending on the damaging agent. When touched, it is dry and feels like processed clothes leather;

- 4<sup>th</sup> degree – in this case, the underlying tissues (hypodermal fat, muscles, etc) are also destroyed<sup>1</sup>.

Apart of the depth of the burn, its surface area is also a very important prognostic factor. The most frequently used method for its assessment relative to the total body surface is that of the nines<sup>7</sup>. The body areas are divided in 9% or multiple by 9%: head 9%, front side of the body 2×9%, back side of the body 2×9%, left lower extremity 2×9%, right lower extremity 2×9%, left upper extremity 9%, right upper extremity 9%, perineum and genitals 1%.

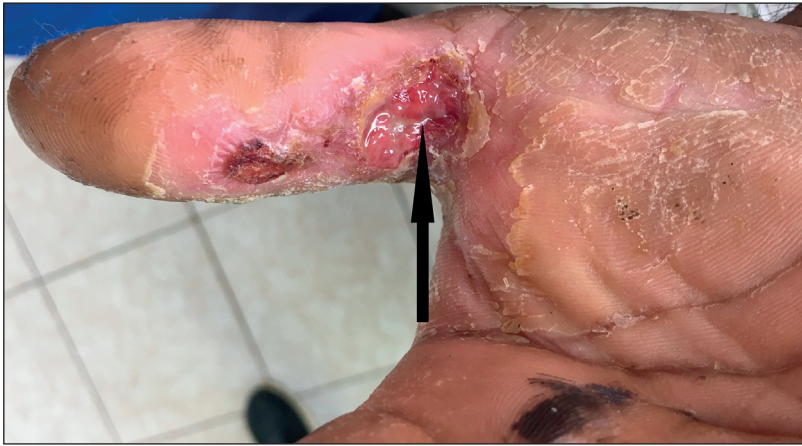The treatment of burns is a difficult and slow process and directly depends on their depth, area and injuring agent. Surgical and non-surgical methods are used, their goal being the following: pain reduction, prevention of infection, removal of avital tissues, preventing the formation of coarse scars, keloids and contractures of the joints or if the patient has them, they to be as minimal as possible and finally overcoming the consequences<sup>1</sup>.

We present here two clinical cases of 3<sup>rd</sup> degree limited burns, initially treated by necrectomy and antiseptic silver dressings, and after that alternatively with Theresienöl.

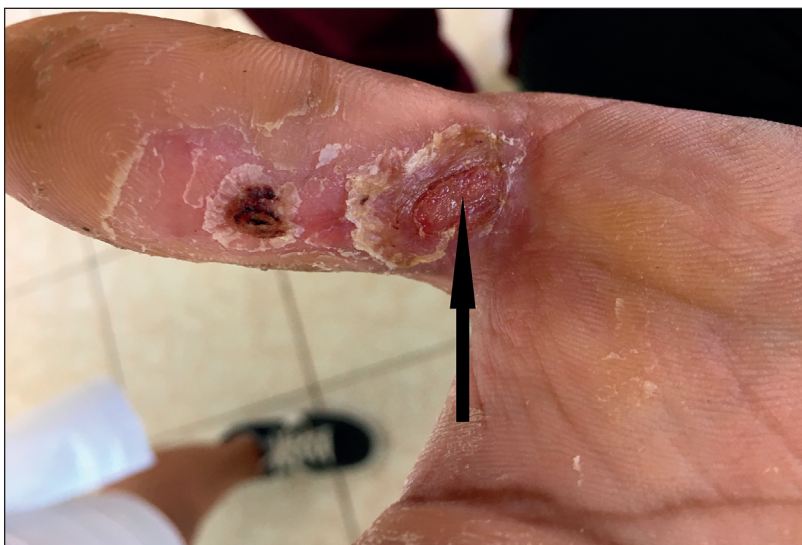## CASES PRESENTATION

### First clinical case

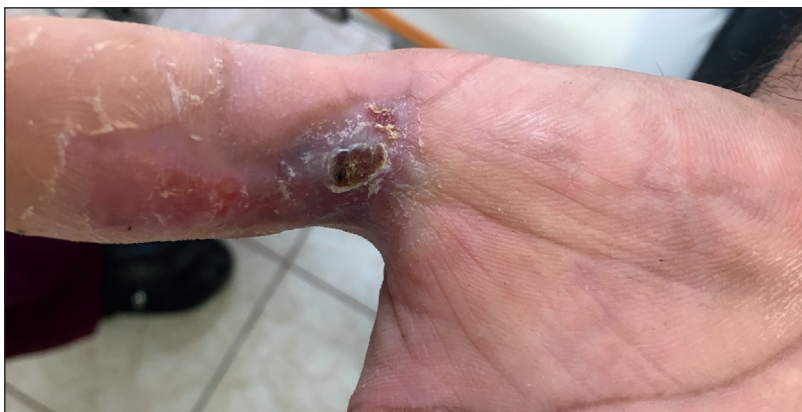A 36-year-old man was hospitalized with a diagnosis of 3<sup>rd</sup> degree electric burn, with a surface under 1%, at the base of right hand, first finger. The patient underwent necrectomies of the site to healthy tissues, immediately after his hospital admission.



**Figure 1.** The 3<sup>rd</sup> degree burn site prior to treatment with Theresienöl.



**Figure 2.** The 3<sup>rd</sup> degree burn site a week after the treatment with Theresienöl.



**Figure 3.** Completely healed wound after 14-day treatment with Theresienöl.

Postoperatively, local, antiseptic treatment with silver dressings for about 14 days was applied. We noted unsatisfactory healing, with presence of suppurative exudate in the wound bottom, and decided to move on to local treatment with 2 drops of Theresienöl once daily, covering the site with wet gauze, to avoid the oil soaking in (Fig. 1).

Seven days later, the patient presented for a follow up, and we saw that the wound was almost

half the size, with no signs of infection (Fig. 2). We decided to continue with the same local treatment regimen, until complete healing.

After another 7 days, the patient came again for a follow up. After taking off the dressing, we saw that the wound was completely healed, with a normal cicatrix, which didn't disturb the functionality of the hand (Fig. 3).



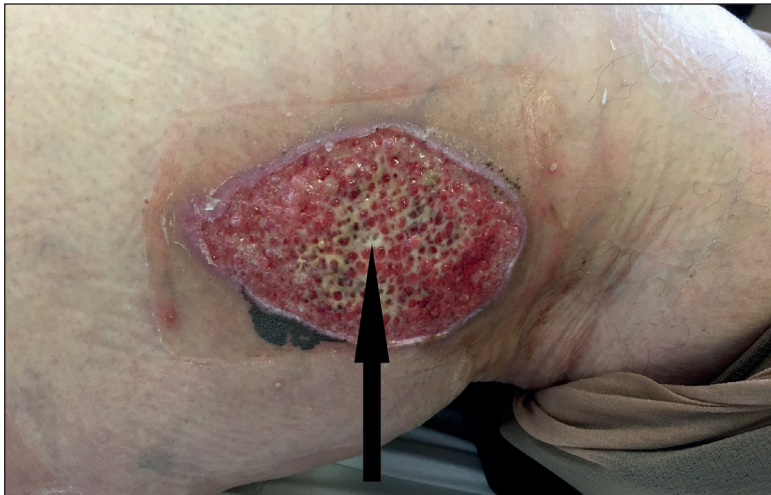

Figure 4. 3<sup>rd</sup> degree burn site prior to treatment with Theresienöl.

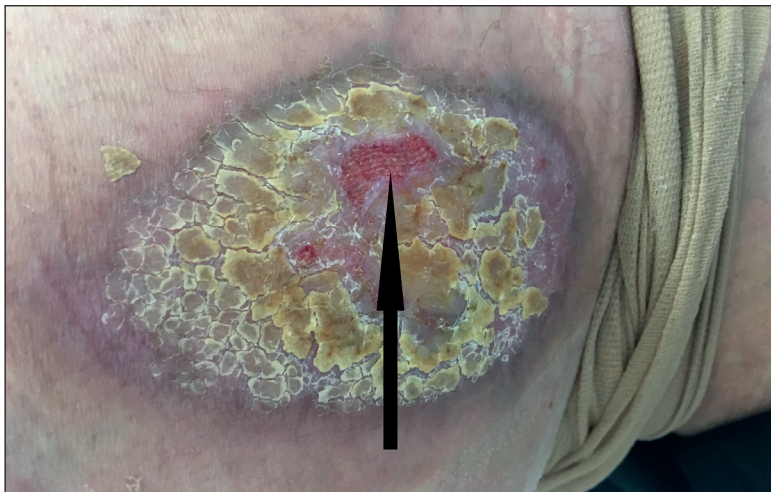


Figure 5. 3<sup>rd</sup> degree burn site 1 month after treatment with Theresienöl.

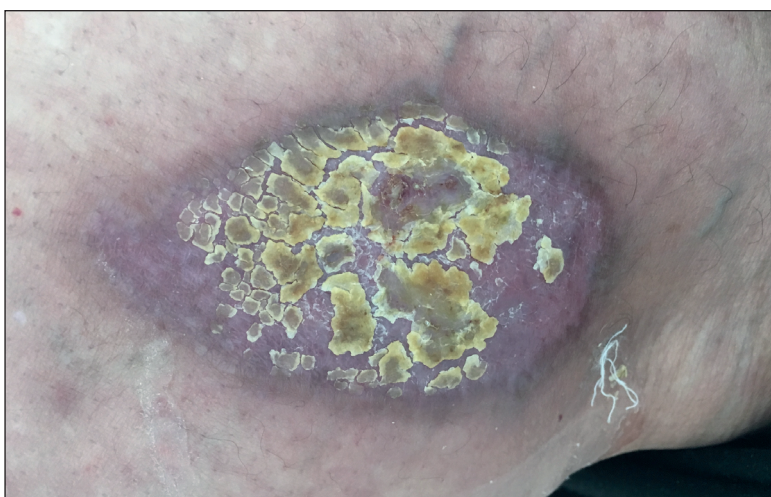

Figure 6. Completely healed wound after 37 days of treatment with Theresienöl.

### Second clinical case

A 68-year-old woman was hospitalized with a diagnosis of 3<sup>rd</sup> degree, 1% burn by hot water, located on right thigh, mid third lateral section. As an emergency measure, we undertook surgically neurectomies of the site to visibly healthy tissues. We applied antiseptic dressings with nano-silver. About 2 weeks

later, we observed local granulations, with evidence of infection – suppurative matter was present (Fig. 4).

We decided that the treatment was not adequately effective and started an alternative treatment, with 10 drops of Theresienöl once daily, on the site, under wet gauze, aiming to avoid its resorption. A month later, we had a follow up check of the wound, for its



assessment. We observed that the wound was healed about 90% (Fig. 5).

We continued the same local treatment, and at the last follow up, 7 days later, we found out that the burn site is completely healed, while the scar had normal anatomic characteristics, without local functional impairment (Fig. 6).

## DISCUSSION

The treatment of 3<sup>rd</sup> degree burns is difficult and slow, because of the entire destruction of the skin layers, which automatically excludes the initiation of the restorative processes of the injury site. These restorative processes start from the neighbouring healthy tissues. For this purpose, all local factors that impede the process, such as necrosis and infections, should be removed.

Initially, in this type of burns, it is mandatory to start with surgical removal of necrosis to healthy tissues<sup>1,8,9</sup> or, very rarely, with the use of enzymes for this process<sup>1,10-15</sup>. Until fresh granulations appear, antiseptic dressings are laid, usually containing silver<sup>1,16-19</sup>, to prevent site infection, after which flap skin transplantations to cover the affected area are undertaken. Unfortunately, only small burns can heal without the need of skin transplant and it takes long time. Often, hypertrophic cicatrices with contractures appear at these sites. Waiting for the spontaneous healing of larger 3<sup>rd</sup> degree burns, which happens even more slowly, increases the risk of severe local infection, accompanied by sepsis. In these cases, the formation of hypertrophic cicatrices with contractures is a rule<sup>1</sup>.

In the clinical cases presented, we found out that the postoperative, local, antiseptic treatment is ineffective, since infection of the affected sites appeared. This impedes the use of flap skin plastic procedures as treatment option at this moment, because of the risk of postoperative septic lesion of the graft. For this reason, our team took a decision for local, alternative treatment with Theresienöl, prior to the future flap skin plastic procedure. The oil application brought about complete recovery of the affected sites, with no need of plastic recovery and within a not too long period.

Theresienöl is an oil containing a combination of herbal extracts, the recipe of which is kept in deep secret from an Austrian family for over 6 centuries now. Its analgesic effect strongly reduces the pain caused by burn. Its antiseptic effect leads to strong reduction of the microbes' number at the damaged site. The anti-inflammatory, hydrating and stimulating effects on granulations and epithelization result in faster and complete healing. All the above-mentioned

clearly explains the clinical results that we have obtained.

## CONCLUSION

Theresienöl may be a good alternative to the free skin graft plastics, when it refers to 3<sup>rd</sup> degree small size burns.

### Compliance with Ethics Requirements:

„The authors declare no conflict of interest regarding this article“

„The authors declare that all the procedures and experiments of this study respect the ethical standards in the Helsinki Declaration of 1975, as revised in 2008(5), as well as the national law. Informed consent was obtained from all the patients included in the study“

„No funding for this study“

## REFERENCES

- Hermans M. A general overview of burn care. *Int Wound J*. 2005;2:206–220.
- DeToledo J, Lowe M. Microwave oven injuries inpatients with complex partial seizures. *Epilepsy Behav*. 2004;5(5):772-774.
- Josty I, Mason W, Dickson W. Burn wound management in patients with epilepsy: adopting a multidisciplinary approach. *J Wound Care*. 2002;11(1):31-34.
- Sances A, Myklebust J, Larson S, et al. Experimental electrical injury studies. *J Trauma*. 1981;21(8):589-597.
- Sykes R, Mani M, Hiebert J. Chemical burns: retrospective review. *J Burn Care Rehabil*. 1986;7(4):343-347.
- Pulla R, Pickard L, Carnett T. Frostbite: an overview with case presentations. *J Foot Ankle Surg* 1994;33(1):53-63.
- Lund C, Browder N. The estimate of area of burns. *Surg Gynecol Obstet*. 1944;79:352-358.
- Jackson D, Topley W, Cason J, et al. Primary excision and grafting of large burns. *Ann Surg*. 1969;167:152-157.
- Janzekovic Z. Early surgical treatment of the burned surface. *Panminerva Med* 1972;14(7–8): 228-32.
- Hermans M. Results of a survey on the use of different treatment options for partial and full thickness burns. *Burns*. 1998;6:539-55
- Herndon D, Barrow R, Rutan R, et al. A comparison of conservative versus early excision. Therapies in severely burned patients. *Ann Surg* 1989;209(5):547-52 (discussion 552-3)
- Rosenberg L, Lapid O, Bogdanov-Berezovsky A, et al. Safety and efficacy of a proteolytic enzyme for enzymatic burn debridement: a preliminary report. *Burns*. 2004; 30(8):843-850.
- Levenson S. Supportive therapy in burn care. Debriding agents. *J Trauma*. 1979;19(11 Suppl): 928-930.
- Hansbrough J, Achauer B, Dawson J, et al. Wound healing in partial-thickness burn wounds treated with collagenase ointment versus silver sulfadiazine cream. *J Burn Care Rehabil* 1995;16(3 pt 1):241-7.
- Ozcan C, Ergun O, Celik A, et al. Enzymatic debridement of burn wound with collagenase in children with partial-thickness burns. *Burns* 2002;28(8):791-4.

16. Innes M, Umraw N, Fish J, et al. The use of silver coated dressings on donor site wounds: a prospective, controlled matched pair study. *Burns* 2001;27(6):621-7.
17. Caruso D, Foster K, Hermans M, et al. Aquacel Ag in the management of partial-thickness burns: results of a clinical trial. *J Burn Care Rehabil* 2004;25(1):89-97.
18. Parsons D, Bowler P, Walker M. Polishing the information on silver. *Ostomy wound manage* 2003;49(8):10-1 (author reply 11-2, 14, 16 passim).
19. Demling R, DeSant L. Effects of silver on wound management. *Wounds* 2001;13(1):23-8.