

## FETAL TOPOGRAPHY OF ARTERIES AND NERVES OF MUSCLES OF THE MEDIAL FEMORAL GROUP

Tatiana V. KHMARA<sup>1</sup>✉, Pavlina V. HRYHORIEVA<sup>1</sup>, Svitlana D. NOVYCHENKO<sup>1</sup>,  
Olga P. KHAPITSKA<sup>2</sup>

<sup>1</sup> Higher State Educational Institution of Ukraine „Bukovinian State Medical University“, Chernivtsi, Ukraine

<sup>2</sup> National Pirogov Memorial Medical University, Vinnytsya, Ukraine

Received 24 July 2019, Accepted 05 Oct 2019

<https://doi.org/10.31688/ABMU.2019.54.4.04>

### ABSTRACT

**Introduction.** A clear knowledge on the variations of blood supply and innervation of muscles in different areas of the body allows the surgeon to select the neurovascular pedicle, when performing muscle transposition operations using microsurgical techniques, to correctly choose the muscle flap, the method of replacing the defect and the localization of the donor area.

**The objective of the study:** to clarify the information about the sources of innervation and blood supply to the gracilis muscle, adductor muscles and pectineus muscles, as well as to investigate the intramuscular distribution of nerves and arteries in the muscles of the medial group of the thigh in human fetuses aged 4-10 months.

**Materials and methods.** The peculiarities of the fetal topography of the arteries and nerves of the medial femoral group muscles were studied in 42 human fetuses aged 4-10 months using the methods of macro microscopic preparation, vascular injection, surface staining of the prepared vessels and nerves, and morphometry.

**Results.** It has been established that the distribution of nerves and arteries is uneven in the thickness of the muscles of the medial group of the thigh, at the same time the middle third of all adductor muscles is

### RÉSUMÉ

**Topographie fœtale des artères et des nerfs des muscles du groupe fémoral médial**

**Introduction.** Une bonne connaissance des variations de l'irrigation sanguine et l'innervation des muscles dans différentes zones du corps permet au chirurgien de choisir le pédicule neurovasculaire lors de la transposition musculaire à l'aide de techniques microchirurgicales, de choisir correctement le lambeau musculaire, de remplacer le défaut et la localisation de la zone donneuse.

**Le but de l'étude:** clarifier les informations sur les sources d'innervation et d'approvisionnement en sang du muscle gracilis, des muscles adducteurs et des muscles pectinés, ainsi qu'étudier la distribution intramusculaire des nerfs et des artères dans les muscles du groupe médial de la cuisse chez le fœtus humain âgé de 4 à 10 mois.

**Matériaux et méthodes.** Les particularités de la topographie fœtale des artères et des nerfs des muscles du groupe fémoral médial ont été étudiées chez 42 fœtus humains âgés de 4 à 10 mois en utilisant les méthodes de préparation macromicroscopique, d'injection vasculaire, de coloration de surface des vaisseaux et des nerfs préparés et de la morphométrie.

✉ Address for correspondence:

Tetiana V. KHMARA  
Higher State Educational Institution „Bukovinian State Medical University“,  
Chernivtsi, 58001, Ukraine  
E-mail: khmara.tv.6@gmail.com; Phone: +38 099 751 65 50

supplied with blood and innervated more intensively. The places where nerves penetrate into the thickness of the muscles of the medial femoral group, do not coincide with the places where the arteries enter, pectineus muscle is an exception. The nature of the intramuscular distribution of nerves and arteries depends on the structure and function of the muscle. The intramuscular nerve trunks are interconnected in the gracilis and adductor magnus muscles, forming loops and arcades. Nerve connections between the obturator and sciatic nerves are found in the thickness of the adductor magnus muscle.

**Conclusions.** In the picture of the intramuscular distribution of nerves and arteries in the muscles of the medial group of the thigh in human fetuses, three forms can be distinguished: loose, trunk, and mixed. In the thickness of the muscles of the medial femoral group, the distribution of nerves and arteries is uneven. Segmentation is preserved in the intramuscular distribution of arteries in the muscle gracilis, adductor longus and magnus muscles, while in the distribution of nerves in these muscles segmentation is absent.

**Keywords:** gracilis muscle, adductor muscles, pectineus muscle, blood supply, innervation, fetus.

## INTRODUCTION

Traffic accidents, injuries caused by explosions, battle wounds, surgical and orthopedic manipulations (for example, after a syndrome of prolonged compression or tumor resection) or injuries occurring during sports that lead to acute and significant loss of muscle tissue (VML – volumetric muscle loss) are the most frequent causes of skeletal muscle injuries. Damages resulting in more than 20% of muscle mass loss need reconstructive surgical procedures<sup>1</sup>.

Profound knowledge of the age and individual anatomical variability of human skeletal muscles lies in the basis for the successful use of numerous methods of plastic surgery. Clear awareness of the variations of blood supply and innervation of muscles in different areas of the body allows the surgeon to select the neurovascular pedicle, when performing muscle transposition operations using microsurgical techniques, to correctly choose the muscle flap, the method of replacing the defect and the localization of the donor area<sup>2</sup>. Connections between nerves are recognized by clinicians as an important form of

**Résultats.** Il a été établi que la distribution des nerfs et des artères est inégale dans l'épaisseur des muscles du groupe médial de la cuisse, tandis que le tiers moyen de tous les muscles adducteurs est alimenté en sang et innervé plus intensément. Les endroits où les nerfs pénètrent dans l'épaisseur des muscles du groupe fémoral médial ne coïncident pas avec ceux où les artères pénètrent, le muscle pectiné est une exception. La nature de la distribution intramusculaire des nerfs et des artères dépend de la structure et de la fonction du muscle. Les troncs nerveux intramusculaires sont interconnectés dans les muscles gracilis et grand adducteur, formant des boucles et des arcades. Les connexions nerveuses entre les nerfs obturateur et sciatique se trouvent dans l'épaisseur du muscle grand adducteur.

**Conclusions.** Dans l'image de la distribution intramusculaire des nerfs et des artères dans les muscles du groupe médial de la cuisse chez les fœtus humains, trois formes peuvent être distinguées: lâche, tronc et mixte. Dans l'épaisseur des muscles du groupe fémoral médial, la distribution des nerfs et des artères est inégale. La segmentation est préservée dans la distribution intramusculaire des artères en muscle gracilis, des muscles grand adducteur et long adducteur, tandis que dans la distribution des nerfs de ces muscles, la segmentation est absente.

**Mots-clés:** muscle gracilis, muscles adducteurs, muscle pectiné, irrigation sanguine, innervation, fœtus.

compensatory mechanisms of peripheral innervation in nerve injury<sup>3,4</sup>.

Surgical treatment of VML mainly involves the rehabilitation of scar tissue and / or muscle transposition. Autologous muscle transplantation is usually performed in a clinical case when after trauma, tumor resection or nerve damage, large areas of muscle loss occur, which significantly impairs motor function. Surgeons transplant healthy muscle from a donor site that is not affected by damage to restore lost or impaired function. In the absence of an adjacent muscle due to a high level of nerve damage or a severe injury, autologous muscle transplantation in the form of free functional transplantation can be applied. Gracilis muscle transplantation is usually used to repair the elbow joint after injury to the brachial plexus. In this case, the muscle flap can cause a progressive incidence of the donor area and innervation insufficiency. Moreover, up to 10% of these reconstructive surgeries result in complete graft rejection due to complications such as infection and necrosis<sup>1</sup>.

The obturator canal syndrome results from compression of the obturator nerve (L2-L4) in the obturator canal due to fibrosis, osteophytes of the

pubic bones, hernia of the canal, traumatic swelling of soft tissues and is manifested by pain and sensory disturbances on the inner surface of the knee joint (Hauship-Romberg phenomenon), spasms or paresis of the adductor femoral muscles – while walking in the phase when the leg is in the air, there is an excessive abduction of the foot<sup>5,6</sup>. It should be noted that the obturator nerve syndrome may be one of the clinical manifestations of aneurysm of the common iliac vein<sup>7</sup>.

The contractures of the hip joints in patients with spastic forms of cerebral palsy with the restoration of abduction and extension of the thigh are eliminated by semi-closed adductotomy (from „puncture“ accesses up to 5 mm) at the medial site of attachment of the adduction femoral group with the restoration of abduction of the hips at least for 60 degrees. In teenagers with the developed arthrogenic contracture and in previously operated patients, adductotomy is performed openly and with the intersection of all scar-modified tissues, with the exception of the adductor brevis muscle of the thigh<sup>8</sup>.

However, the peculiarities of the intramuscular distribution of nerves and arteries in the muscles of the lower limb are currently presented quite insufficiently in the most common guidelines on neurology, vascular surgery, traumatology and orthopedics<sup>9,12</sup>. In the available sources there is practically no information about the fetal topography of the vessels and nerves of the muscles of the lower extremities, and in particular of the thigh. This study is a continuation of our earlier research on blood supply and innervation of the muscles of the lower limb<sup>13-16</sup>. All these indicate that the study of the intramuscular distribution of nerves and arteries in the muscles of the thigh in human fetuses is an important task not only for fetal anatomy, but also for perinatal medicine in general.

**THE OBJECTIVE OF THE STUDY** was to clarify information about the sources of innervation and blood supply to the gracilis, adductor and pectineus muscles, as well as to investigate the intramuscular distribution of nerves and arteries in the muscles of the medial femoral group in human fetuses aged 4-10 months.

## MATERIALS AND METHODS

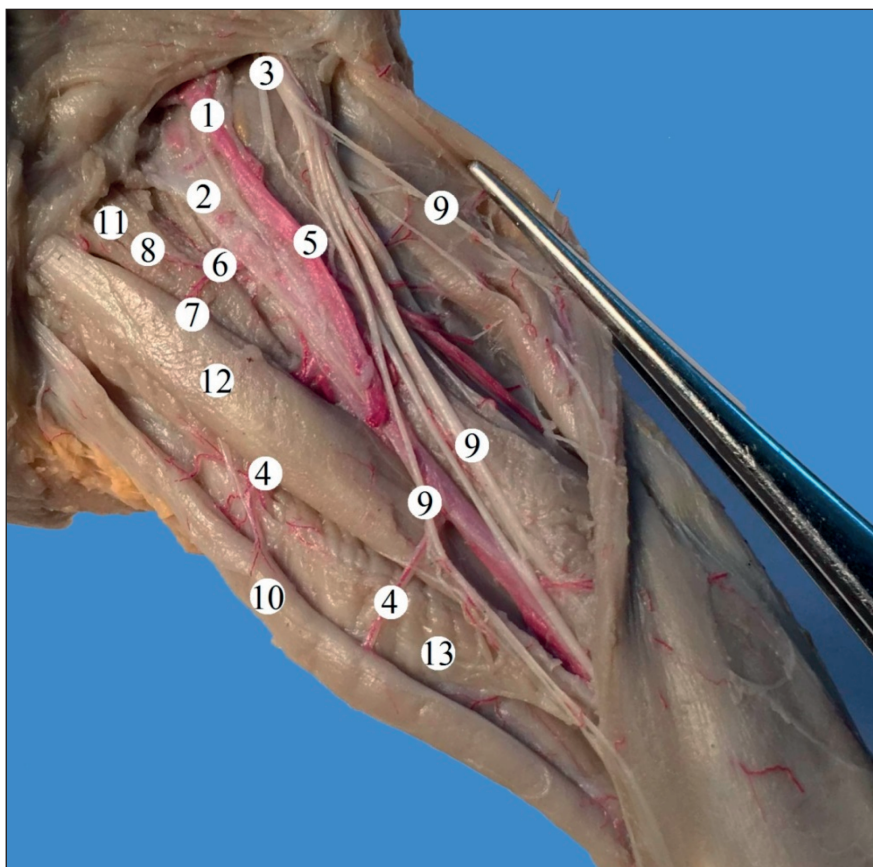
Preparations of the lower extremities of 42 human fetuses of 81.0-375.0 mm of crown-rump length (CRL) without developmental anomalies were studied using macro microscopic preparation, vascular injection, surface staining of prepared vessels and nerves, and morphometry. Preparations of fetuses weighing more than 500.0 g were studied directly in the Chernivtsi Oblast Children's Pathology Bureau under

a cooperation agreement. The study also involved fetus preparations from the museum of the Department of Human Anatomy named after M.H. Turkevych and the Department of Histology, Cytology and Embryology of Bukovinian State Medical University, Ukraine. The surface staining of the prepared vessels and nerves was performed in the following sequence:

1. Autopsied specimen with prepared vessels and nerves was first laid on a tray and slightly dried with filter paper.
2. After that, it was kept open at room temperature for 20-30 minutes.
3. Only the vessels and nerves that were clearly visible to the naked eye were stained, a magnifying glass can be used to control the staining.
4. „Gouache“ for artistic and design works was used for staining, fine brushes – for watercolors. The paint was diluted with water to a uniform state and applied with a brush to vessels, or nerves, starting from their main trunks. Red color was used for arteries, blue – for veins, and yellow or white – for nerves.
5. The order of staining of neurovascular structures should correspond to the topography and the depth of their location relative to each other. This must be observed for the convenience of consistent application of paint, so as not to smear the adjacent structures with other colors.
6. After staining, the specimen was left to dry for 15-20 minutes, and then the prepared 5% gelatin solution was spread over the entire surface of the specimen. Gelatin was applied with a soft brush, slightly touching the specimen.
7. The specimen was again left to dry for 10-15 minutes to let gelatin coagulate and immersed in 10% formalin solution, which fixes the stained-gelatinous coating and makes it no longer soluble.

It should be noted that after such staining, the specimen can be placed in a container for hermetic storage in a museum exposition, and photographed repeatedly, including under water for scientific and educational purposes.

The studies were performed in compliance with the main bioethical provisions of the Council of Europe Convention on Human Rights and Biomedicine (04/04/97), Helsinki Declaration of the World Health Association on the ethical principles of conducting medical research with human participation (1964-2013), the Order of the Ministry of Health of Ukraine No. 690 of September 23, 2009, and taking into account the methodological recommendations of the Ministry of Health of Ukraine „The procedure for the removal of biological objects from the dead, whose bodies are subject to forensic examination and post-mortem examination, for scientific



**Fig. 1.** Vessels and nerves of the left anterior femoral region of a male fetus of 135.0 mm of CRL. Macro specimen. Magnified 2.4 $\times$ :

- 1 – femoral artery; 2 – femoral vein; 3 – femoral nerve; 4 – muscle branches of the femoral artery;  
 5 – deep femoral artery; 6 – medial artery, circumflexing the femoral bone; 7 – superficial branch;  
 8 – ascending branch; 9 – muscle branches of the femoral nerve; 10 – gracilis muscle; 11 – pectineus muscle;  
 12 – adductor longus muscle; 13 – adductor magnus muscle.

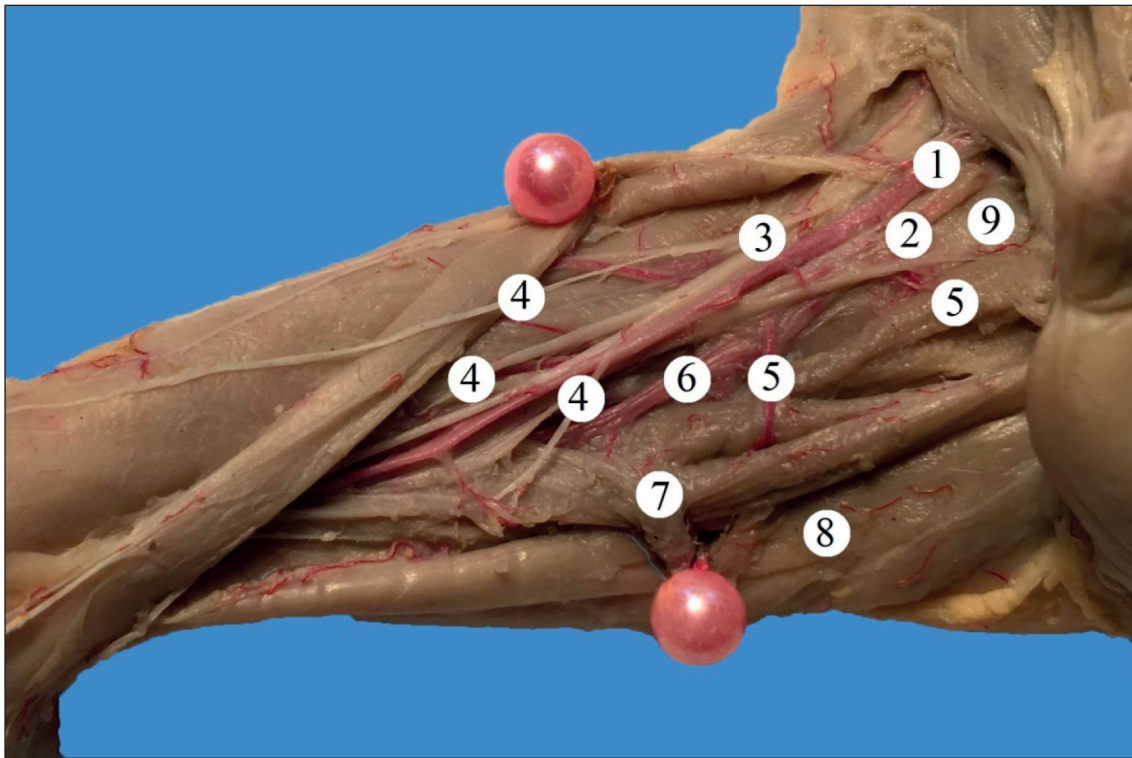
purposes (2016). The Commission on Biomedical Ethics of the Bukovinian State Medical University has not revealed any violations of bioethical and moral norms during the conduct of scientific research.

## RESULTS AND DISCUSSION

It has been established that in human fetuses, from 3 to 6 arterial and nerve trunks enter into the gracilis muscle from its posterior surface and lateral edge. It should be noted that in the majority of fetuses the vessels and nerves go together, occasionally, as a rule, at the level of the lower third of the gracilis muscle they occur separately. The upper third of the gracilis muscle is supplied with blood by the superficial and ascending branches of the medial artery, circumflexing the femoral bone, the anterior branch of the obturator artery; 2-3 muscle branches of the femoral artery supply blood to the middle third of the myogaster (Fig. 1). The upper and middle third of the gracilis muscle is innervated by the anterior

and muscular branches of the obturator nerve and in isolated cases – by the muscle branches of the femoral nerve. The lower third of the gracilis muscle is supplied with blood by 2-3 muscle branches of the femoral artery, the descending genicular artery and is innervated by the muscle branches of the femoral nerve. It should be emphasized that, in relation to the longitudinal axis of the gracilis muscle, the arterial trunks are transversely arranged, and the main nerve trunks are placed longitudinally relative to the obturator nerve. The nerve trunks, as well as the arteries of the 2<sup>nd</sup> and 3<sup>rd</sup> orders, are parallel to each other. Arteries in the gracilis muscle are branched according to the mixed type, and intramuscular nerves in the region of the upper and middle thirds of the muscle, mainly according to the trunk type, and in the region of its lower third, as a rule, according to the loose type. Segmentation is preserved in the intramuscular distribution of arteries in the gracilis muscle, while segmentation is absent in the distribution of nerves in this muscle. Within the middle and lower thirds





**Fig. 2.** Vessels and nerves of the right anterior femoral region of a male fetus of 135.0 mm of CRL. Macro specimen. Magnified 2.4<sup>x</sup>:

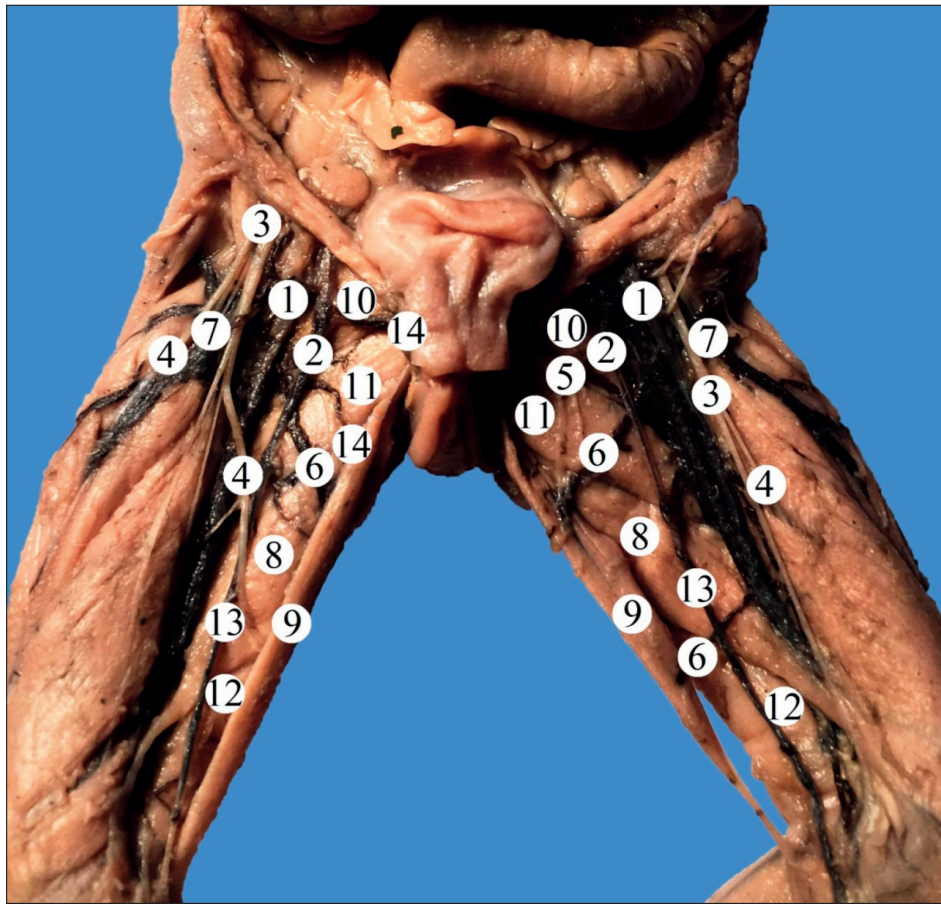
- 1 – femoral artery; 2 – femoral vein; 3 – femoral nerve; 4 – muscle branches of the femoral nerve;  
5 – muscle branches of the femoral artery; 6 – descending genicular artery; 7 – adductor longus muscle;  
8 – gracilis muscle; 9 – pectineus muscle.

of the gracilis muscle, the descending nerve trunks, as a rule, are connected to the lateral branches of the adjacent nerve trunks, forming loops and arcades. Anastomoses between the intramuscular arteries in the gracilis muscle were not detected.

The upper third of the adductor longus muscle is supplied with blood by the muscle branches from the obturator artery and the medial artery, circumflexing the femoral bone, the middle and lower thirds of this muscle – by the 1-3 muscle branches from the femoral artery and (or) the deep femoral artery. Intramuscular arterial anastomoses were observed in isolated cases. The arteries approach the adductor longus muscle from the posterior (mainly branches of the obturator artery) and the anterior (indicated branches of the femoral artery system) surfaces, their entry points are located along the entire length of the muscle. In this case the segmental type of blood supply prevails. The nerve trunks of the obturator nerve enter the adductor longus muscle from its posterior surface at the border of the transition of the upper third of the myogaster to the middle third. The middle third of the adductor longus muscle is more intensively supplied with arteries and nerves. Nerves branch out according to the mixed, or less often to the trunk type,

without segmentation in the distribution of nerves. The direction of the large diameter of the intramuscular arteries and the main nerve trunks does not coincide with the direction of the muscle bundles of the adductor longus muscle. Only nerve trunks of the 2<sup>nd</sup> and 3<sup>rd</sup> orders lie in the thickness of the adductor longus muscle parallel to the direction of the muscle bundles. In eleven observations, 1-2 muscle branches from the femoral nerve (Fig. 2, 3) were directed to the middle and (or) lower thirds of the myogaster of the adductor longus muscle, branching out in its thickness according to the mixed type.

The blood supply of the adductor brevis muscle is provided by the branches of the obturator and perforating arteries, which go to the muscle from its anterior surface, as well as by the muscle branches of the femoral artery. Places of entry of nerves in the muscle do not coincide with the places of entry of arteries. Nerve trunks enter the thickness of the adductor brevis muscle from its anterior surface arising from the anterior branch of the obturator nerve. In this case the middle third of the adductor brevis muscle is more intensively supplied with both arteries and nerves. The loose type prevails in the distribution of the nerve and arterial branches in the thickness of



**Fig. 3.** Vessels and nerves of the anterior femoral regions of the female fetus of 170.0 mm of CRL. Macro specimen. Magnified 2.1<sup>x</sup>:

- 1 – femoral artery; 2 – femoral vein; 3 – femoral nerve; 4 – muscle branches of the femoral nerve;  
 5 – obturator nerve; 6 – muscle branches of the femoral artery; 7 – deep femoral artery; 8 – adductor longus muscle;  
 9 – gracilis muscle; 10 – pectineus muscle; 11 – adductor brevis muscle; 12 – adductor magnus muscle;  
 13 – great saphenous vein; 14 – external pudendal veins.

the adductor brevis muscle. However, in the picture of the branching of nerves, no neural connections were detected. It should also be noted that the arterial network is poor in anastomoses. In two cases, the adductor brevis muscle was innervated by the anterior and posterior branches of the obturator nerve.

The blood supply to the upper third of the adductor magnus muscle is provided by the posterior branch of the obturator artery, the deep branch of the medial artery, circumflexing the femoral bone, the muscle branches of the femoral artery; the middle and lower thirds of the muscle are supplied with blood by the perforating arteries. In 6 cases, the lower third of the adductor magnus muscle was supplied with blood by the medial superior genicular artery from the popliteal artery system. The above arteries enter into the thickness of the adductor magnus muscle from the anterior and posterior surfaces, in these cases the segmentation is pronounced in the branching of the arteries. The largest arteries in diameter

enter the muscle from the anterior surface, usually in the region of the middle third of the myogaster. The main arterial trunks in relation to the direction of the muscle bundles are located transversely, and the final branching of the arteries are located in the thickness of the adductor magnus muscle parallel to the direction of its muscle bundles. The places where the nerves enter the adductor magnus muscle do not coincide with the places where the arteries enter. In this case, the places of entry of nerves and arteries are located on two opposite surfaces of the adductor magnus muscle. The sources of innervation of the adductor magnus are the obturator and sciatic nerves. The nerve trunks enter the thickness of the adductor magnus from both sides, mainly at an acute angle, in this case in the branching picture of the anterior and posterior branches of the obturator nerve, segmentation is lost. The ramifications of the anterior branch of the obturator nerve in the thickness of the muscle are mainly distributed according to the trunk

type, and of the posterior branch – according to the loose type. The middle third of the muscle belly of the adductor magnus muscle is supplied with nerves more intensively than its proximal and distal parts. Intramuscular nerve connections were found in the thickness of the adductor magnus muscle between the systems of the two nerves.

It should be noted that the intramuscular nerves often give off nerve trunks to the intramuscular vessels, to the skin and to the periosteum.

The places of entry of arteries and nerves in the adductor brevis muscle are located on the side of the anterior surface of the muscle belly. In this case, the gate of entry of the nerves do not coincide with the places of entry of the arteries. The number of arteries entering the thickness of the adductor brevis is variable. Sources of blood supply to the adductor brevis muscle are the obturator and perforating arteries. Larger arterial branches enter the middle third of the muscle belly and branch out on the superficial layer of the muscle. Arterial trunks of the 2<sup>nd</sup> and 3<sup>rd</sup> orders branch out in the deep layer of the adductor brevis muscle. Intramuscular arteries are characterized by a significant anatomical variability. The direction of the intramuscular arteries coincides with the direction of the muscle bundles of the adductor brevis. Nerves branch out in the thickness of the adductor brevis muscle by a mixed type, and arteries, as a rule, by a loose type. The adductor brevis muscle was absent in two cases.

The pectineus muscle is innervated by the trunk of the femoral nerve, as well as by the anterior branch of the obturator nerve, while in the thickness of the muscle there are no connections between the terminal branches of these nerves. Sources of blood supply to the pectineus muscles are the obturator and deep external pudendal arteries, as well as the branches of the deep artery of the thigh, as a rule, the superficial and ascending branches of the medial artery, circumflexing the femoral bone. It is characteristic that the direction of the nerves in the thickness of the pectineus muscle coincides with the direction of the arteries.

The vascular-neuro-muscular apparatus of the lower extremities has long attracted the attention of researchers. Currently, the least studied is the intramuscular distribution of blood vessels and nerves in the muscles of the thigh in human fetuses and, as a result, the connections between the neurovascular structures in the thickness of the muscles have not been fully represented. Meanwhile, the practical tasks of restoring impaired function of the lower extremity with the help of myoplastic operations, as well as muscle repair of residual bone cavities, for example, at osteomyelitis, require further in-depth study of not

only extra-, but also intramuscular neurovascular relationships, especially in connection with the structural peculiarities of muscles in different periods of pre- and postnatal human ontogenesis.

The main issue of the research in this paper was the study of the intramuscular distribution of nerves and arteries and their interrelations in the medial group of the femoral muscles in human fetuses. When studying this issue, it was revealed that not all the muscles of the medial femoral group are equally intensively supplied with intramuscular nerves and arteries, and not all muscles have the same degree of individual anatomical variability<sup>17</sup>.

As a result of the study, the variability of the number of nerves and vessels that supply the muscles of the medial group of the thigh, the levels and angles of origin and their penetration into the thickness of the muscles, and, especially, the form of their intramuscular distribution was investigated.

It is established that a large number of intramuscular nerves branch out in the gracilis muscle, dynamic in its function. It should also be noted that the direction of the intramuscular nerves does not coincide with the direction of the intramuscular arteries in all the muscles of the medial group of the thigh. Even the type of intramuscular branching of nerves and arteries in the same muscle can differ<sup>18</sup>.

The source of nerves in the muscles of the medial femoral group is the lumbosacral plexus. These muscles are predominantly supplied with blood by the branches of the femoral and obturator arteries. All the muscular arteries can be divided into major and accessory. Accessory arteries can often be absent. Each muscle of the medial group of the thigh has several places of arterial entrance, with more arterial branches than nerve trunks penetrating each muscle.

Places of entry of nerves, as a rule, do not coincide with the places of entry of arteries<sup>14, 15, 19</sup>.

In a number of muscles of the medial group of the thigh (gracilis and adductor magnus muscle), the intramuscular nerve trunks are interconnected, forming loops and arcades. The application of the method of macro microscopic preparation made it possible to detect neural connections between the obturator and sciatic nerves in the thickness of the adductor magnus muscle<sup>20</sup>.

## CONCLUSIONS

1. In the picture of the intramuscular distribution of nerves and arteries in the muscles of the medial group of the thigh in human fetuses, three forms can be distinguished: loose, trunk, and mixed. In the thickness of the muscles of the medial femoral group the distribution of nerves and arteries is



- uneven. The middle third of all adductor muscles is more intensively supplied with blood and innervated.
- The gate of nerve entry into the thickness of the muscles of the medial group of the thigh, with the exception of the pectineus muscle, does not coincide with the places where the arteries enter. Places of entry of nerves and arteries can be located both on the anterior and posterior surface of the muscle belly. Places of the entry of nerves and arteries are located on two opposite surfaces of the muscle only in the adductor magnus muscle.
  - The nature of the intramuscular distribution of nerves and arteries depends on the structure and function of the muscle. In the intramuscular distribution of arteries in the gracilis muscle, adductor longus and magnus, segmentation is preserved, while in the distribution of nerves in these muscles segmentation is absent.
  - The muscles with double innervation are the adductor magnus and pectineus muscles, and as an option, the adductor longus muscles. In muscles with double innervation, intramuscular nerve connections between systems of different nerves are found only in the thickness of the adductor magnus muscle.

#### Compliance with Ethics Requirements:

„The authors declare no conflict of interest regarding this article“

“The authors declare that all the procedures and experiments of this study respect the ethical standards in the Helsinki Declaration of 1975, as revised in 2008(5), as well as the national law. Informed consent was obtained from all the patients involved in the study“

„No funding for this study“

#### REFERENCES

- Liu J, Saul D, Böker KO, Ernst J, Lehman W, Schilling AF. Current methods for skeletal muscle tissue repair and regeneration. *Biomed Res Int.* 2018; 2018: ID 1984879. doi: 10.1155/2018/1984879
- Guérin P, Obeid I, Gille O, et al. Safe working zones using the minimally invasive lateral retroperitoneal transpsoas approach: a morphometric study. *Surg Radiol Anat.* 2011; 33(8):665-71.
- Bowley MP, Doughty CT. Entrapment neuropathies of the lower extremity. *Med Clin North Am.* 2019;103(2):371-382.
- Meadows JR, Finnoff JT. Lower extremity nerve entrapments in athletes. *Curr Sports Med Rep.* 2014;13(5):299-306.
- Beltran LS, Bencardino J, Ghazikhanian V, Beltran J. Entrapment neuropathies III: lower limb. *Semin Musculoskelet Radiol.* 2010;14(5): 501-11.
- Craig A. Entrapment neuropathies of the lower extremity. *PMR.* 2013; 5(5 Suppl): 31-40.
- Brinegar KN, Sheth RA, Khademhosseini A, Bautista J, Oklu R. Iliac vein compression syndrome: Clinical, imaging and pathologic findings. *World J Radiol.* 2015;7(11): 375-381.
- Shamsoddini A, Amirsalari S, Hollisaz MT, Rahimnia A, Khatibi-Aghda A. Management of spasticity in children with cerebral palsy. *Iran J Pediatr.* 2014; 24(4): 345-351.
- Donovan A, Rosenberg ZS, Cavalcanti CF. MR imaging of entrapment neuropathies of the lower extremity. Part 2. The knee, leg, ankle, and foot. *Radiographics.* 2010; 30(4):1001-19.
- Origoni M, Maggiore ULR, Salvatore S, Candiani M. Neurobiological mechanisms of pelvic pain. *Biomed Res Int.* 2014; 2014: ID 903848. doi: 10.1155/2014/903848
- Brejt N, Berry J, Nisbet A, Bloomfield D, Burkill G. Pelvic radiculopathies, lumbosacral plexopathies, and neuropathies in oncologic disease: a multidisciplinary approach to a diagnostic challenge. *Cancer Imaging.* 2013;13(4):591-601.
- Bayramollu M. Entrapment neuropathies of the lower extremities. *ACU Saġlık Bil Derg.* 2017;(4):185-191.
- Yasar S, Kaya S, Temiz C, Tehli O, Kural C, Izci Y. Morphological structure and variations of lumbar plexus in human fetuses. *Clin Anat.* 2014;27(3):383-8.
- Dong Q, Jacobson JA, Jamadar DA, et al. Entrapment neuropathies in the upper and lower limbs: anatomy and MRI features. *Radiol Res Pract.* 2012; 2012: ID 230679. doi: 10.1155/2012/230679
- Khmara TV, Komar TV. Individual anatomical variability in the innervation of thigh and calf muscles in human fetuses. *Deutscher Wissenschaftsherold German Science Herald.* 2016;3: 3-6.
- Khmara TV, Hryhorieva PV, Vasylyshchyna IV, Tsyhykalo AV, Zamorskii II, Ryznychuk MA. Anatomic variability of branches of iliac and femoral arteries in human fetuses. *Arch Balk Med Union.* 2019; 54(1): 11-21.
- Abe SI, Ishizawa A, Nasu H, et al. Human fetal topographical anatomy of the femoral triangle in relation with change in the hip joint position. *Okajimas Folia Anat Jpn.* 2014; 91(1): 5-12.
- Turgut M, Protas M, Gardner B, Oskouian RJ, Loukas M, Tubbs RS. The accessory obturator nerve: an anatomical study with literature analysis. *Anatomy.* 2017;11(3): 121-127.
- Sakthivelavan S, Sendiladibban SD, Felicia C. Branching pattern of fetal internal iliac artery. *Rev Arg de Anat Clin.* 2010; 2(3):100-105.
- Rohini M, Yogesh AS, Banerjee C, Goyal M. Variant accessory obturator nerve? A case report and embryological review. *Journal of Medical and Health Sciences.* 2012; 1: 7-9.