

ORIGINAL PAPER

THE ROLE OF SHEAR WAVE ELASTOGRAPHY IN THE DYNAMIC MONITORING OF FIBROSIS IN PATIENTS WITH CHRONIC HEPATITIS C WITH SUSTAINED VIROLOGICAL RESPONSE AFTER DIRECT ACTING ANTIVIRAL THERAPY

Mihaela C. OLARIU^{1,2}✉, Elena L. STOICHITOIU³, Adriana NURCIU², Gabriela ANDRIESCU¹, Mihai H. OLARIU², Camelia C. DIACONU^{1,4}

¹ University of Medicine and Pharmacy „Carol Davila“, Bucharest, Romania

² National Institute of Infectious Diseases „Matei Bals“, Bucharest, Romania

³ Colentina Clinical Hospital, Bucharest, Romania

⁴ Clinical Emergency Hospital of Bucharest, Romania

Received 18 Sept 2019, Accepted 07 Nov 2019

<https://doi.org/10.31688/ABMU.2019.54.4.12>

ABSTRACT

Introduction. In the last years, the non-invasive methods of evaluating liver fibrosis were imposed in the current medical practice.

The objective of the study was to evaluate the role of 2D Shear Wave elastography in the dynamic monitoring of liver fibrosis compared to a validated method – Fibromax.

Materials and methods. 37 patients with chronic hepatitis C infection and advanced fibrosis (F3/F4) who received treatment with Paritaprevir/Ritonavir + Ombitasvir + Dasabuvir were included. The evaluation was done at baseline, 12 weeks after the end of treatment and 48 weeks after therapy.

Results. There was a significant and positive correlation of high degree, according to the Spearman's rho correlation coefficient, between 2D Shear Wave elastography and Fibromax, showing very similar results both at the beginning of therapy ($p < 0.001$, $R = 0.726$)

RÉSUMÉ

Le rôle de l'élastographie par ondes de cisaillement dans le monitoring dynamique de la fibrose chez des patients présentant une hépatite C chronique avec réponse virologique soutenue suite à une thérapie antivirale directe

Introduction. Au cours des dernières années, la pratique médicale actuelle a imposé des méthodes non invasives d'évaluation de la fibrose hépatique.

L'objectif de l'étude était l'évaluation du rôle de l'élastographie 2D par ondes de cisaillement dans le suivi dynamique de la fibrose par rapport à une méthode validée – Fibromax.

Matériaux et méthodes. 37 patients atteints d'hépatite C chronique et de fibrose avancée (F3 / F4) traités par Paritaprevir / Ritonavir + Ombitasvir + Dasabuvir ont été inclus à l'étude et l'évaluation a été réalisée au

✉ Address for correspondence:

Mihaela C. OLARIU
National Institute of infectious Diseases“Prof. Dr. Matei Bals“, Bucharest,
Romania
Address: Dr. Grozovici Str., No.1, Bucharest, Romania
E-mail: ol_cristina@yahoo.ro

and one year after its completion ($p < 0.001$, $R = 0.961$). The correlation between platelet count and the non-invasively estimated liver fibrosis degree is statistically significant, being moderately negative ($p = 0.009$, $R = 0.426$) – patients with low platelet count at baseline did not present an improvement of fibrosis or it was not statistically significant one year after stopping the treatment. Direct antiviral therapy with Paritaprevir/Ritonavir + Ombitasvir + Dasabuvir, besides the chronic hepatitis C eradication rate of 99-100%, also determines a statistically significant improvement ($p < 0.001$) of the degree of liver fibrosis.

Conclusions. There is a strong correlation between the two non-invasive methods analyzed, which recommends routine use of 2D Shear Wave elastography alone or in combination with other tests. In addition to the remarkable effectiveness of the therapeutic regimen used (SVR rates $> 95\%$), there is also a significant improvement of fibrosis, which prevents progression to cirrhosis and hepatocellular carcinoma.

Keywords: elastography, two-Dimensional shear wave elastography, Fibromax, chronic hepatitis C, hepatic fibrosis.

Abbreviations

2D-SWE = 2-Dimensional Shear Wave Elastography
 ALT = alanine aminotransferase
 DAA = direct-acting antiviral agent
 Exviera – Dasabuvir
 HCV – Hepatitis C Virus
 M0 = baseline, before starting the treatment
 M1 = 6 months after starting the treatment
 M2 = 12 months after end of the treatment
 Viekirax – Ombitasvir/Paritaprevir/Ritonavirum

INTRODUCTION

New non-invasive means of diagnosing and monitoring liver fibrosis have been developed. It is important to focus on the safest and most accurate method and validate it, since liver biopsy is still considered the gold standard in evaluating liver fibrosis, despite the fact that it has many pitfalls¹. Persistent infection with hepatitis C virus (HCV) is the leading cause of chronic liver disease, with an estimated 1.75 million new HCV infections diagnosed in 2015¹. Direct antiviral therapy is now curative, but it is estimated that only 20% of individuals who are chronically infected with HCV are diagnosed and only 15% of those diagnosed are treated¹. Disease progression is accelerated by male sex, viral infection at a more advanced age, obesity, consumption of alcohol in high quantities, HIV co-infection and immunosuppression²⁻⁴.

début, 12 semaines après la fin du traitement et 48 semaines après le traitement.

Résultats. Il y avait une corrélation positive et significative de haut degré selon le coefficient de corrélation de Spearman rho entre l'élastographie 2D par ondes de cisaillement et Fibromax montrant des résultats très similaires au début du traitement ($p < 0,001$, $R = 0,726$) et un an après son achèvement ($p < 0,001$, $R = 0,961$). La corrélation entre la numération plaquettaire et le degré estimé non invasif de fibrose hépatique est statistiquement significative, elle est modérément négative ($p = 0,009$, $R = 0,426$) – les patients présentant une numération plaquettaire faible au départ n'ont pas enregistré d'amélioration de la fibrose ou elle n'a pas été statistiquement significative un an après l'arrêt du traitement. La thérapie antivirale directe avec Paritaprevir / Ritonavir + Ombitasvir + Dasabuvir en plus du taux d'éradication chronique de l'hépatite C de 99-100% détermine également une amélioration statistiquement significative ($p < 0,001$) du degré de fibrose hépatique.

Conclusions. Il existe une forte corrélation entre les deux méthodes non invasives analysées, qui recommande l'utilisation systématique d'élastographie 2D par ondes de cisaillement, seule ou en combinaison avec d'autres tests. Outre l'efficacité remarquable du schéma thérapeutique utilisé (taux de RVS $> 95\%$), il existe également une amélioration significative de la fibrose qui empêche la progression de la cirrhose et du carcinome hépatocellulaire.

Mots-clés: élastographie, élastographie par ondes de cisaillement bi-dimensionnelles, Fibromax, hépatite chronique C, fibrose hépatique.

Without treatment, chronic HCV infection lead to liver cirrhosis (15-30% risk within 20 years), liver failure and hepato-carcinoma (risk of 2-4% per year)⁵⁻⁷.

A crucial step before starting the treatment is the assessment of liver disease severity, by determining the degree of fibrosis^{8,9}. The gold standard for the diagnosis and staging of liver fibrosis is liver biopsy, although the procedure is limited by sampling error, variability and procedure-related complications, like bleeding and pain¹⁰. Over the time, new tests have been developed and Fibromax has proved a good predictive value and, most importantly, a better benefit-to-risk ratio. FibroMAX combines five non-invasive tests in a single method, in order to calculate all the fibrosis-related tests: FibroTest for the quantitative assessment of fibrosis, SteatoTest for the quantitative assessment of steatosis, ActiTest for the quantitative assessment of necro-inflammatory activity in chronic

viral hepatitis C and B, Nash Test for the categorical diagnosis of nonalcoholic steatohepatitis and Ash Test for the quantitative assessment of alcoholic steatohepatitis¹¹.

Since FibroMAX, elastography has emerged and imposed as a useful tool for fibrosis evaluation, two-dimensional shear wave elastography (2D-SWE) being one of the newest elastographic methods¹². 2D-SWE provides a quantitative estimation of tissue stiffness regarding to the speed of a shear wave, with the advantages that tissue stiffness is acquired in real time, during ultrasound examination, it is not limited to a single location and it is guided to a high frame-rate B-mode image, demonstrating good reliability and reproducibility¹³⁻¹⁵. As far as we know, there is no study which aimed to evaluate the 2D-SWE role in the dynamics monitoring of fibrosis degree in patients with chronic hepatitis C and sustained viral response after treatment with direct-acting antiviral agents (DAAs).

THE OBJECTIVE OF THE STUDY was to prove the role of shear wave elastography in monitoring the dynamics of the fibrosis and the efficacy of the therapy over the fibrosis degree in patients with chronic hepatitis C who have achieved sustained viral response after therapy with DAAs.

MATERIALS AND METHODS

We diagnosed chronic hepatitis C according to the World Health Organization (WHO) Guidelines, in patients with anti-HCV antibodies which remained positive at the second test (six months from the first one), with a quantitative assay of HCV - RNA confirming HCV-viremia³. We used for the evaluation of liver fibrosis' degree with 2D-SWE, the following cut-off values: healthy people < 5kPa, 5kPa ≤ F0-F1/ F1 < 7.1kPa, 7.1kPa ≤ F2 < 9.2 kPa, 9.2 kPa ≤ F3 < 13 kPa, F4 ≥ 13 kPa⁹.

This is an observational, retrospective cohort study. The protocol was approved by the Ethical Committee of „Matei Bals“ National Institute of Infectious Diseases, Bucharest, Romania.

Patients with chronic infection with hepatitis C virus admitted to the Gastroenterology Department of „Matei Bals“ Institute in Bucharest, Romania, from September 2015 to September 2018, were included in the study. Only the patients with available electronic health records and who signed the informed consent were included. Other inclusion criteria were: chronic infection with hepatitis C virus with detectable HCV-RNA, F3-F4 degree of fibrosis determined with Fibromax or Elastography, alanine aminotransferase result (no matter the absolute value),

patients who were previously treated with Viekirax + Exviera. Patients with no available discharge electronic data were not considered for this study. Also, other exclusion criteria were: infection with hepatitis C virus associating undetectable HCV-RNA, F0-F2 degree of fibrosis (excepting medical staff) and pregnant women. We extracted the information from the observation files of the patients and the electronic system of the hospital.

We documented the demographical, biological and ultrasound data, together with the elastography and Fibromax for each patient. In every patient we had the results of platelets absolute values (determined at M0, M1 and M2), alanine aminotransferase (M0, M1, M2), quantitative assay of HCV-RNA (M0, M1, M2), FibroMAX (M0, M2), 2D-SWE (M0, M1, M2) and spleen size (using ultrasound technique). The abdominal ultrasonography and Shear Wave Elastography were performed by a physician with 10 years of experience in ultrasonography and 3 years of elastography experience, in this way eliminating the inter-observer variability. The standard measurements were performed according to the contemporary recommendations, European Federation of Societies for Ultrasound in Medicine and Biology (EFSUMB) Guidelines and Recommendations on the Clinical Use of Ultrasound Elastography 2013¹⁶, using a Aixplorer® V9.3 echography system. Shear Wave Elastography examination was performed after fasting, with the patient lying in supine position, the right arm in maximum abduction, in the right hepatic lobe, with the probe aligned along the intercostal space. The patients were instructed to hold their breath in the phase of exhalation, while the examiner positioned the elastographic window (approximately 3 cm x 4 cm), 2-3 cm under the liver capsule, in a region free of visible vessels, and measured stiffness in real-time. Stiffness is expressed in kilopascals of Young's modulus. A measurement was considered valid when it fulfilled the following quality criteria: more than 80% (in difficult patients, with abdominal gases, ascites) and over 0% for normal patients, of color filling the elasticity map and a measurement circular Q-box of at least 1.3 cm in diameter, free of visible artifacts like speckled color. Only examinations with 3 valid measurements for patients with known liver disease and 6 valid measurements for patients investigated for the first time were considered to be reliable and we kept the mean value of the successful measurements as representative for liver stiffness. All the patients also underwent Fibromax testing on the same day or within several days.

Statistical analysis. We used IBM SPSS Statistics 20 and Microsoft Office Excel/Word 2013. A p value less than 0.05 was considered statistically significant.

Quantitative variables were tested for distribution using Shapiro-Wilk test and were expressed as median ± standard deviations if the parameters had a normal distribution and as median and interquartile range if they had a non-gaussian distribution. Categorical variables were expressed as absolute values or percentages. Independent numerical variables with a non-parametric distribution were tested using Mann-Whitney U and the correlations were assessed using the Spearman's rank correlation coefficient (Spearman's Rho). Independent numerical variables with a parametric distribution were tested using Student T-Test, and the existing correlations were assessed using the Pearson's correlation coefficient. Comparison of numerical variables were assessed using the Related-Samples Friedman's Two-Way Anova test for normal distributed parameters and the One-Way Anova with repeated measures for the non-parametric variables. Qualitative variables were tested using Fisher's Exact Test/Pearson Chi-Square and their correlations were assessed using Pearson's contingency coefficient. Post-hoc paired analysis was done for the paired quantitative variables using Wilcoxon or Paired Samples T-Test.

RESULTS

Our cohort included 37 patients, most of them over 60 years-old (65%) and with female predominance (65%).

The correlation between the degree of fibrosis before starting the treatment and age was significant and positive, of moderate degree for both methods we analyzed (R=0.400, p=0.014 – elastography and r=0.485, p=0.002 – Fibromax), but age did not correlate with fibrosis response to treatment (p=0.830).

The patient's sex correlated positively with fibrosis regression after treatment, with men presenting more frequently a better outcome regarding fibrosis degree dynamics than women (R = 0.416, p = 0.017 – Fibromax and R = 0.344, p = 0.047 – elastography).

The fibrosis degree at one year after treatment completion correlated negatively with platelets' number at baseline (R = - 0.448, p = 0.005 Fibromax, R = - 0.426, p = 0.009 Elastography) and positively with spleen size at baseline (R = 0.603, p < 0.001 Fibromax, R = 0.551, p<0.001, elastography).

The platelets number was significantly lower before starting treatment, post-hoc analysis showing significant differences between their absolute value when comparing M0 with M1(p=0.005) and M2 (p=0.0035), without notably improvement in platelets count in patients with favourable fibrosis outcome, assessed with Fibromax (p= 0.896) or elastography (p=0.960).

Post-hoc analysis regarding fibrosis' degree assessed with elastography demonstrated a significant difference only between M0 and M2 (p=0.009), with lower grades of fibrosis at the end of the treatment (medium range =1.7 vs medium range =2.39) (Fig. 1).

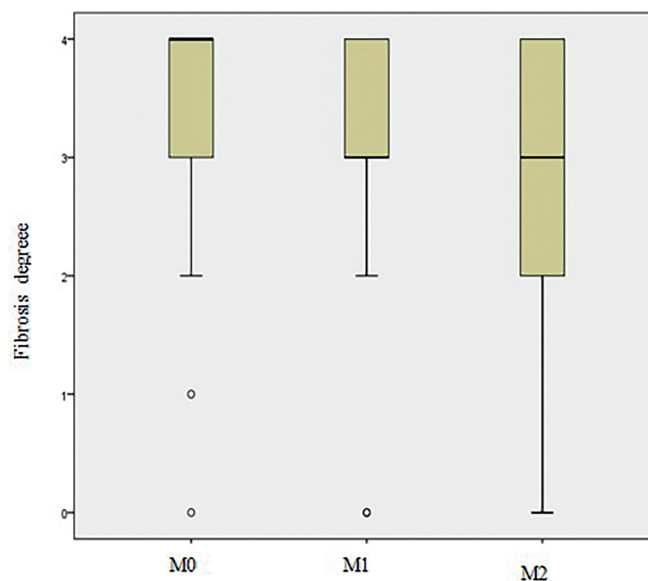


Figure 1. Fibrosis degree dynamic at M0, M1 and M2 according to Two-Dimensional Shear Wave Elastography. Fibrosis degree was significantly lower onlu at the end of the treatment.

M0 = baseline, before starting the treatment, M1 = 6 months after starting the treatment, M2 = 12 months after finishing the treatment

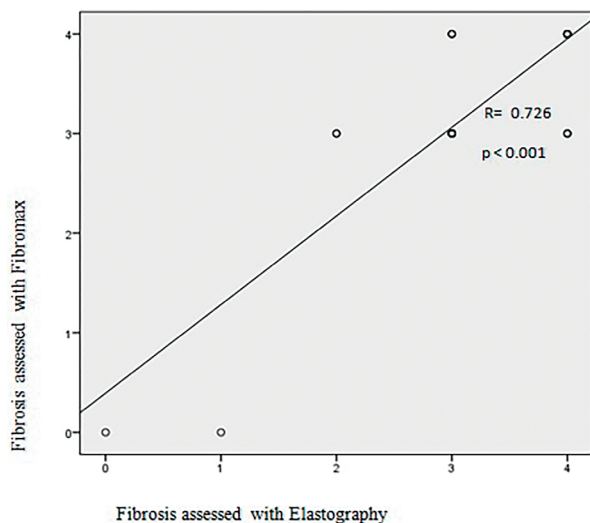


Figure 2. Correlation between fibrosis degree measured at the beginning of the treatment using Elastography and Fibromax. Fibrosis degree was very similar at the beginning of the treatment when assessed with both 2D-SWE and Fibromax.

2S-SWE = two-dimensional shear wave elastography

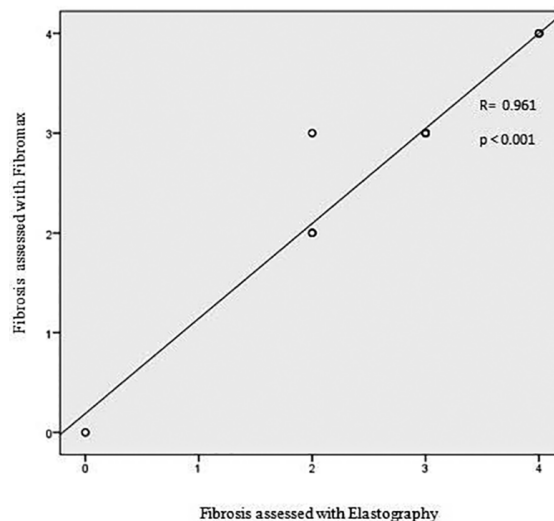


Figure 3. Correlation between fibrosis degree measured at the end of the treatment using Elastography and Fibromax. Fibrosis degree was very similar at the end of the treatment when assessed with both 2D-SWE and Fibromax.

2S-SWE = two-dimensional shear wave elastography

Fibrosis reversibility degree after treatment did not depend neither on serum viremia ($p=0.177$ elastography, $p=0.118$ Fibromax) nor steatosis degree at baseline ($p=0.873$ Fibromax, $P=0.630$ Elastography).

Fibrosis degree assessed with elastography at six months after treatment completion correlated negatively with alanine aminotransferase value at 12 months after treatment completion ($R=-0.392$, $p=0.016$).

Fibrosis degree assessed with elastography and Fibromax correlated positively and in a high degree, not only before starting the treatment, but also one year after its completion ($R=0.726$, $p<0.001$ respectively $R=0.961$, $p<0.001$) (Fig. 2, Fig. 3).

DISCUSSION

According to patients' distribution by sex, it can be noted a slightly higher percentage of women compared to males (64.9%). This could be explained, at least in Romania, by the presence of several risk factors in women (abortions, births, surgery, blood transfusions), especially before the 90s, men presenting more frequently a better outcome regarding fibrosis' degree dynamics when compared to women¹⁷⁻¹⁹.

The correlation between the age of the patients and the degree of hepatic fibrosis estimated noninvasively, using 2D-SW Elastography and FibroMax, is significant and positive of moderate degree. Thereby, patients between 60-80 yo had significantly higher

degrees of fibrosis at baseline, but age did not correlate with fibrosis' response to treatment ($p=0.830$).

Hepatic fibrosis (estimated noninvasively both by 2D-SW Elastography and FibroMax) is significantly correlated with certain clinical-biological parameters. The results of our study show a significant negative inverse correlation between platelet count at baseline and the fibrosis' degree measured at one year after end of therapy. Furthermore, patients with larger spleen size at M0 had significantly higher degrees of fibrosis one year after the end of treatment, whereas in patients with normal spleen size there was an improvement in the degree of fibrosis after treatment.

The degree of fibrosis reversibility is neither influenced by the value of viremia nor by the degree of steatosis at baseline, but it correlates negatively with the alanine aminotransferase value at 12 weeks post-end of treatment.

The most important objective of this study was to observe the effect of a sustained viral response (SVR) on fibrosis progression. All patients included in the study obtained SVR, but in addition, the degree of fibrosis - estimated noninvasively both by biological test (FibroMax) and elastography (2D-SW Elastography) - significantly improved one-year post-therapy.

The secondary objective was to demonstrate the correlation between the two noninvasive methods for assessing fibrosis (FibroMax and 2D-SW Elastography). The obtained results showed that

there is a very significant correlation between the two methods in the evaluation of fibrosis, both at the beginning of the treatment and one year after its completion.

Thus, we consider that 2D-SW Elastography can be used both in the initial evaluation of the patients and in their evaluation/monitoring on a long-term basis.

The combined use of noninvasive fibrosis assessment methods (FibroMax and 2D-SW Elastography) increases diagnosis accuracy.

The present study is intended as a starting point for a prospective study that will include a higher number of patients, with several antiviral therapeutic schemes and monitored for long term.

CONCLUSIONS

The main result of the study attests that the direct antiviral therapy with Ombitasvir/Paritaprevir/Ritonavir + Dasabuvir improves fibrosis besides the viral eradication. Evaluation of fibrosis before treatment and one year after its completion with the help of 2D-SW Elastography shows a statistically significant difference ($p < 0.001$).

2D-SW Elastography has a very important role in the assessment of fibrosis and this study indicates that the evaluation of fibrosis obtained by FibroMax and by this elastographic method are strongly similar. There is a significant and positive correlation of high degree between the two methods, both at baseline ($p < 0.001$, $R = 0.726$) and one year after the end of treatment ($p < 0.001$, $R = 0.961$).

Compliance with Ethics Requirements:

„The authors declare no conflict of interest regarding this article“

“The authors declare that all the procedures and experiments of this study respect the ethical standards in the Helsinki Declaration of 1975, as revised in 2008(5), as well as the national law. Informed consent was obtained from all the patients included in the study“

„No funding for this study“

REFERENCES

- Hui-Chun Li, Shih-Yen Lo. Hepatitis C virus: Virology, diagnosis and treatment. *World Journal of Hepatology* 2015;7(10):1377-1389.
- Spearman CW, Dursheiko GM, Hellard M, Sanderup M. Hepatitis C. *Lancet* 2019;394:1451-66.
- Diaconescu D, Pantea Stoian A, Socea L, et al. Hepato-renal syndrome: a review. *Arch Balk Med Union* 2018;53(2):239-245.
- Balaceanu A, Diaconu C, Mateescu D, Stanica A. Hepatocellular carcinoma with hepatic and pulmonary metastasis, inferior vena cava and left pulmonary artery thrombosis in a patient with asymptomatic hepatitis C. Case report. *Medical Ultrasonography* 2010;12(4):345-348.
- World Health Organization. Guidelines on Hepatitis B and C testing. <https://www.who.int/hepatitis/publications/guidelines-hepatitis-cb-testing/en/> (Accessed on September 10, 2019).
- Ilie M, Rusu M, Rosianu C, et al. Ultrasound-guided biopsy in focal liver lesions. *Arch Balk Med Union* 2018;53(3):364-368.
- Balaceanu A, Diaconu C, Costache C, Diaconu A. Interrelation between hepatocellular carcinoma and asymptomatic chronic hepatitis C: need for a screening protocol. *Practica Medicala* 2012;VII(3): 256-259.
- Diaconu C, Balaceanu A, Bartos D. Liver function tests anomalies in patients with chronic heart failure. *Medicina Moderna* 2014;21(3):145-149.
- Diaconu CC. Sindromul metabolic. Editura Medicala, Bucharest, 2011.
- Lucero C, Brown Jr RS. Noninvasive measures of liver fibrosis and severity of liver disease. *Gastroenterology & Hepatology*. 2016;12(1): 33-40.
- Morra R, Munteanu M, Imbert-Bismut F, Messous D, Ratziu V, Poynard T. FibroMAX: towards a new universal biomarker of liver disease? *Expert Review of Molecular Diagnostics*, 2007;7(5):481-90.
- Sporea I, Bota S, Gradinaru - Tascu O, Sirli R, Popescu A, Jurchis A. Which are the cut-off values of 2D-Shear Wave Elastography (2D-SWE) liver stiffness measurements predicting different stages of liver fibrosis, considering Transient Elastography (TE) as the reference method? *European Journal of Radiology*. 2014;83:e118-e122
- Poynard T, Pham T, Perrazo H, et al. Real-time Shear Wave versus transient elastography for predicting fibrosis: applicability, and impact of inflammation and steatosis. A non-invasive comparison. *PLoS One*. 2016;11(10): e0163276
- Serra C, Grasso V, Conti F. A new two-dimensional Shear Wave elastography for noninvasive assessment of liver fibrosis in healthy subjects and in patients with chronic liver disease. *Ultraschall Med*. 201;39(4):432-439
- Herman E, de Lédinghen V, Cassinotto C, et al. Assessment of biopsy-proven liver fibrosis by two-dimensional shear wave elastography: An individual patient data-based meta-analysis, *Hepatology*. 2018;67(1): 260-272.
- Cosgrove D, Piscaglia F, Bamber J. EFSUMB Guidelines and Recommendations on the Clinical Use of Ultrasound Elastography. Part 2: Clinical Applications. *Ultraschall in der Medizin / European Journal of Ultrasound* 2013;34(3):238-253.
- Bucur D, Berceanu D, Diaconu C. Hemostasis in patients with cirrhosis: a hazardous balance. *Arch Balk Med Union* 2016;51(4):501-505.
- Balaceanu A, Diaconu C, Aron G. Budd-Chiari syndrome as an initial presentation of hepatocellular carcinoma – a case report. *Medical Ultrasonography* 2014;16(2):172-174.
- Draghici T, Negreanu L, Bratu OG, et al. Liver abnormalities in patients with heart failure. *Arch Balk Med Union* 2018;53(1):76-81.