

ORIGINAL PAPER

TRANSURETHRAL „EN BLOC“ RESECTION TECHNIQUE IN NON-MUSCLE INVASIVE BLADDER CANCER

Ivan VLADANOV¹✉, Alexei PLESACOV¹, Artur COLTA¹, Emil CEBAN¹, Vitalii GHICAVII¹, Ghenadie SCUTELNIC¹

¹Republican Clinical Hospital „Timofei Mosneaga“, Department of Urology and Surgical Nephrology, State University of Medicine and Pharmacy „Nicolae Testemitanu“, Chisinau, Republic of Moldova

Received 18 Febr 2020, Corrections received 29 Mar 2020, Accepted 30 Apr 2020

<https://doi.org/10.31688/ABMU.2020.55.2.07>

ABSTRACT

Introduction. Transurethral resection of the bladder tumours (TURBT) is the standard approach to bladder tumour removal; however, it has several disadvantages.

The objective of the study was to evaluate the safety and efficacy of „en bloc“ resection of non-muscle invasive bladder tumours (ERBT) by using the conventional monopolar „Hook“ resection electrode.

Material and methods. ERBT and TURBT procedures were conducted in 67 and in 85 patients respectively, diagnosed with superficial bladder tumours. In the ERBT group, the tumours were removed retrograde en bloc, under direct vision, via a conventional monopolar „Hook“ electrode. Clinical pathological, intra-operative and post-operative patients' data were compared retrospectively between both groups (ERBT and TURBT).

Results. Of the 152 patients, 67 underwent ERBT and 85 were treated with TURBT. Both groups were comparable in clinical characteristics. ERBT has been performed as safely and effectively as TURBT. There were no significant differences in the operative time and intraoperative or postoperative surgical complications. The comparative recurrence rates were similar

RÉSUMÉ

Technique de la résection transurétrale „en-bloc“ du cancer de la vessie sans envahissement du muscle

Introduction. La résection transurétrale des tumeurs de la vessie (RTUTV) représente l'approche standard à l'égard de l'enlèvement des tumeurs de la vessie. Cependant, elle a plusieurs inconvénients.

L'objectif de l'étude était d'évaluer la sécurité et l'efficacité de la résection „en-bloc“ des tumeurs de la vessie sans infiltration du muscle (ERTV) en utilisant l'électrode de résection monopolaire conventionnel „Hook“.

Matériel et méthodes. Les procédés ERTV et RTUTV ont été menés chez 67 et 85 patients respectivement, diagnostiqués avec tumeurs de la vessie superficielles. Dans le groupe ERTV, les tumeurs ont été enlevées en-bloc de manière rétrograde sous contrôle visuel direct à l'aide d'une électrode monopolaire conventionnel „Hook“. Les données cliniques pathologiques, pré- et post-opératoires des patients des deux groupes (ERTV et RTUTV) ont été comparées rétrospectivement.

Résultats. Des 152 patients, 67 ont été soumis à ERTV et 85 à RTUTV. Les deux groupes de patients

✉ Address for correspondence:

Ivan VLADANOV
Republican Clinical Hospital „Timofei Mosneaga“, Department of Urology and Surgical Nephrology, State University of Medicine and Pharmacy „Nicolae Testemitanu“, Chisinau, Republic of Moldova Email: ivan.vladanov@gmail.com, Phone +373 69244836

for both groups during up to 24-month follow-up. The detrusor muscle fibers were histologically identified in 100% of ERBT tumour samples and marginal tumour bases, and only in 80% of post-TURBT samples.

Conclusions. ERBT is a feasible and safe technique for removing superficial bladder tumours using a monopolar „Hook“ resection, with the same advantages of a proper tumour resection, as well as possibility to collect good quality tumour samples and bladder tumour base specimen for pathological diagnosis and staging compared to standard TURBT.

Keywords: en bloc resection, non-muscle invasive bladder cancer, ERBT, TURBT.

Abbreviations: ERBT – en bloc resection of the bladder tumours, TURBT – transurethral resection of the bladder tumours, NMIBC – non-muscle invasive bladder cancer.

INTRODUCTION

Although urinary bladder cancer is estimated to be the second most frequent urological cancer encountered in the world¹⁻⁴, 70% of the identified cases are non-muscle invasive⁵⁻⁸ and they are usually treated by transurethral resection (TURBT) of the tumour. However, there is a constant need to overcome the conventional technique of piecemeal resection of tumours, due to high-risk cell dissemination in the bladder and poor quality of resected samples, as well as lack of detrusor muscle fragments within the histological tissues and thermal bladder tissue damage.

Appropriate resection, together with establishing a precise histological diagnosis, are essential for the successful management of bladder cancer treatment⁹⁻¹¹.

Currently, the goal of TURBT, which remains the gold standard in the treatment of non-muscle invasive bladder cancer (NMIBC)¹²⁻¹⁴, is to remove all visible and modified tissues for further study and accurate pathological diagnosis¹⁵. The detection of the detrusor muscle within the tissue is the most significant characteristic for postoperative prognosis^{7,16-18}. However, the diagnosis is often inaccurate⁹ due to poor quality¹⁹⁻²² of the samples resulting from resection of tumours and charring of the resected tissues.

THE OBJECTIVE OF THE STUDY was to evaluate the safety and efficacy of „en bloc“ resection of non-muscle invasive bladder tumours (ERBT) by

présentaient des caractéristiques cliniques similaires. ERTV a été réalisé aussi prudemment et efficacement que RTUTV. Il n'y a eu de différences significatives ni entre le temps opératoire, ni entre les complications chirurgicales pré- et post-opératoires. Les taux de rechute comparatifs des deux groupes enregistrés pendant un suivi de 24 mois étaient similaires. Les fibres du détroleur ont été identifiées histologiquement dans 100% des échantillons et des bases tumorales marginales ERTV et seulement dans 68 (80%) des échantillons post-RTUTV.

Conclusions. ERBT est une technique réalisable et sûre pour enlever les tumeurs de la vessie superficielles à l'aide d'une résection monopolaire „Hook“. Cette méthode a les mêmes avantages qu'une résection tumorale, offrant de plus la possibilité de prélever des échantillons de bonne qualité de la tumeur et des spécimens de base tumorale pour le diagnostic pathologique et de stadialisation comparé au standard RTUTV.

Mots-clés: résection en-bloc, cancer de la vessie non-infiltrant le muscle, ERTV, RTUTV.

using the conventional monopolar „Hook“ resection electrode.

MATERIAL AND METHODS

The study was conducted between 01 January 2014 – 30 December 2017, in the Department of Urology and Surgical Nephrology of the Republican Clinical Hospital „Timofei Mosneaga“, Chisinau, Republic of Moldova. The study protocol was approved by the University Ethics committee (N° 4 at 16 December 2019). Statistical description and non-parametric comparison by Fisher exact test were used. The study was conducted according to the ethical standards of the Helsinki declaration of 1975, as revised in 2008. The inclusion criteria in the study were primary non-muscular invasive bladder cancer, age over 18-year-old, and the Eastern Cooperative Oncology Group (ECOG) score 0-2. The exclusion criteria were identified as follows: other non-urothelial tumours, severe comorbidities, ECOG score ≥ 3 and pregnancy.

152 of primarily diagnosed NMIBC patients underwent ERBT and TURBT and were investigated retrospectively. Patients were divided into two groups: the ERBT group (n = 67) and the TURBT group (n = 85) (Table 1, Table 2).

Both techniques were carried out under spinal anesthesia, using the same continuous flow 26Fr resectoscope with monopolar electrode (Karl Storz, Germany) and with cutting and coagulation power

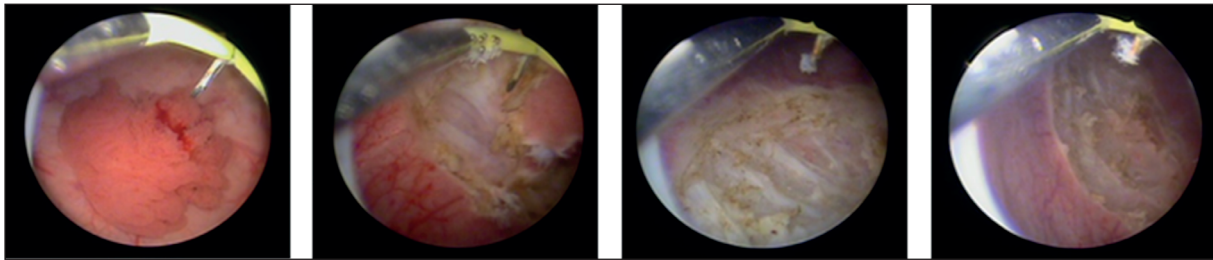


Figure 1. Operating area.

set at 115 and 80 W (Bowa ARC - 400, Germany). Tumours less than 3.0 cm were removed under siphon effect. For tumours larger than 3 cm, the Ellik evacuator was used to retrieve the samples. Biopsy of tumour base was routinely performed with cold forceps after the tumours were resected. The resected tumour was subjected to pathologic evaluation.

In case of „en bloc“ resection of bladder tumour, the resection margins were outlined at approximately 1.0-1.5 cm away from the tumour base, by resecting the normal mucosa in order to coagulate the blood vessels, aiming at reducing intraoperative hemorrhage and spread of tumour cells, as well as separating the tumour base from the bladder wall, after applying gentle pressure. When the deep muscle layer was reached, usually after one or two previous incisions, the tumour base was lifted and pushed away step by step, and the tumour was resected in a single piece. All procedures were performed under direct vision, without the tumour covering the incision site. During the resection, the bleeding vessels were coagulated simultaneously, keeping a clear vision of the operating area (Fig. 1).

Tumours larger than 3 cm were first retrieved superficially by conventional TURBT and the

remaining bases were resected en bloc by ERBT, avoiding their damage²²⁻²⁴.

Intravesical instillation was performed with 40 mg of mitomycin dissolved in 50 ml of 5% glucose solution weekly for 8 weeks, starting one week postoperatively, followed by a monthly maintenance at one year. The patients' follow-up was performed by ultrasonography, cystoscopic examination and urine cytology every 3 months in the first year and 6 months in the next two years. Histological classification and tumour stages were assigned according to World Health Organization 2004 classification²⁵.

RESULTS

This study included 152 patients, who were treated endoscopically by ERBT (67 patients) and TURBT (85 patients). Intraoperative hemorrhage during the procedures was minimal and no blood transfusion was required. These two groups had comparable clinical pathological characteristics, including gender, age, tumour grade, tumour multiplicity, tumour size, and tumour location (Table 1, Table 2). Table 3 shows the characteristics of intra- and postoperative complications in both groups. According to the Clavien-Dindo

Table 1. Patients' data.

Intervention	Age (years)	Tumour size		Gender		Tumour multiplicity	
		≤3cm (n)	>3cm (n)	Male	Female	Single	Multiple
ERBT (n=67)	58.43 ± 8.5	49 (73%)	18 (27%)	57 (85%)	10 (15%)	53 (79%)	14 (21%)
TURBT (n=85)	61.5 ± 12.4	69 (81%)	16 (19%)	66 (77.6%)	19 (22.4%)	69 (81.1%)	16 (18.8%)

ERBT - en-bloc resection of the bladder tumours; TURBT - transurethral resection of the bladder tumours.

Table 2. Characteristics of interventions.

Date	Tumour morphology		Stage		Location				
	Pedunculate	Flat	Ta	T1	Lateral wall	Posterior wall	Anterior wall	Dome	Trigone/bladder neck
ERBT (n=67)	59 (88%)	8 (12%)	35 (52.2%)	32 (47.8%)	38 (56.7%)	6 (9%)	2 (3%)	1 (1.5%)	20 (29.8%)
TURBT (n=85)	74 (87%)	11 (13%)	49 (57.6%)	36 (42.4%)	41 (48.2%)	11 (12.9%)	9 (10.6%)	2 (2.4%)	22 (25.9%)

ERBT - in-block resection of the bladder tumours; TURBT - transurethral resection of the bladder tumours.

Table 3. Results and complications.

Date	Operative time (min)	Complications			Obturator nerve reflex	Bladder perforation
		Grade I	Grade II	Grade III		
ERBT (n = 67)	44 ± 10.5	2 (3%)	8 (12%)	0	10 (15%)	2 (3%)
TURBT (n = 85)	35 ± 14.5	4 (4.7%)	10 (11.7%)	0	11 (13%)	1 (1%)

ERBT – en bloc resection of the bladder tumours; TURBT – transurethral resection of the bladder tumours.

Table 4. Treatment results

Date	Presence of the detrusor muscle					
	Tumour samples	Tumour base	Irrigation (days)	Catheterization (days)	Hospital stay (days)	Follow-up (months)
ERBT (n = 67)	67 (100%)	67 (100%)	0	3.2 ± 1.8	4.01 ± 1.4	16 ± 5.2
TURBT (n = 85)	65 (76%)	68 (80%)	1.0	3.8 ± 2.04	4.2 ± 0.63	18 ± 4.3

ERBT – en bloc resection of the bladder tumours; TURBT – transurethral resection of the bladder tumours

classification for surgical complications, only grade I and grade II complications occurred in each group. Intraoperative obturator nerve reflex occurred in both groups (15% and 13%, respectively). Two patients (3%) in ERBT group and 1 (1%) in TURBT group had bladder perforation, which was managed by catheterization for 4 days. Morpho-pathological examination showed that fragments of detrusor muscle were detected in both tumour samples and tumour biopsies of all ERBT patients, suggesting proper resection of tumour. However, detrusor muscle could only be detected in 80% of the tumour base biopsies in TURBT patients. Additionally, the morphological examination of the resected fragments showed that the lamina propria in the ERBT group remained intact compared to the severe thermal lesions in the TURBT group.

All interventions were performed with a single cystoscopy procedure during up to 24-month follow-up. (Table 4). Most recurrences occurred in patients with high-grade histological recurrence and probably did not require a previous resection.

DISCUSSION

Currently, TURBT remains a standard surgical procedure for non-muscle invasive bladder cancer^{16,20,26,27}. However, up to 51% of samples do not contain detrusor muscle, thus showing a high rate of incomplete resection of up to 78% and a high recurrence rate (50-70%)^{4,10,14,26,28}. Nevertheless, en bloc resection of bladder tumour (ERBT) could reduce the recurrence rate due to a deeper and more complete removal of the tumour and reduction of its dispersion^{10,12,13,20,29}.

Recently, innovative resectoscope modifications or alternative instruments have been proposed to achieve the qualitative „en bloc“ resection. Initially,

„en bloc“ resection allowed resection by making a circular incision around the tumour and including a 0.5 cm safety margin with a needle-shaped electrode^{5,30,31}.

A relatively new idea was the grasp and bite technique, which can be effectively applied to small, flat, and sessile tumours, but may not be suitable for larger tumours^{22,32,33}. The laser is another effective alternative energy source to perform en bloc resection of bladder tumour^{5,26}. In addition to modified electrical loops and proposed laser systems, water-jet-induced enucleation has been reported^{11,30,34,35} to prove feasibility of en bloc resection in tumours sized up to 7.5 cm^{18,36,37}.

In this study, we reported another feasible and safe en bloc resection technique, using only a resectoscope and a conventional loop, without any additional equipment. The safety and efficacy of the new technique were comparable to conventional TURBT. Each „small incision“ of ERBT was performed under direct visual control, which reduced the risk of cutting the bladder wall too deeply or perforating it. Once the tissue is visible, we make sure that the depth of the incision is fully secured. Usually, only one or two „small cuts“ are required to reach the muscle layer.

In order to avoid damage to the surrounding mucosa and bladder perforation, the electrode movement is rapid in conventional TURBT, leading to difficult control of the resection depth^{1,11,38,39}. However, the resection was performed step by step without haste by using „small“ cutting energy, and was safer than common resection⁷.

The risk of obturator nerve stimulation during the procedure was 15% with ERBT and 13% with TURBT, which is the main cause for bladder perforation. However, by using a muscle relaxant, obturator

reflex could be reduced^{25,27,28,40,41}. Only a few cases of bladder perforation occurred in patients from both groups. All patients were discharged after 4-5 days of catheterization, without complications.

According to the literature, there is increasing evidence that ERBT preserves the quality of the resected samples^{2,5,13,42}. The presence of muscle fibers in the tumour sample is essential for an accurate differentiation between T1 and T2^{9,12,14,41}. However, conventional TURBT inevitably results in fragmented tumour resection, with poor anatomic orientation due to piecemeal resection^{4,43}. This will cause a substantial risk in underestimating mainly the patients whose TURBT samples do not contain muscle fibers^{20,25,44-46}. In addition, the existence of lamina propria in the ERBT samples, without any obvious tumour cells, could facilitate a proper pathological diagnosis^{24,29,30,47,48}.

The presence of muscle fibers in tumour base biopsy in the ERBT group was 100%, while in the TURBT group it was only 80%. Moreover, only 76% of resected samples by TURBT included lamina propria compared to 100% in the ERBT group. The low rate of muscle fiber presence, both in the resected samples and tumour base biopsy in TURBT, was due to incomplete resection^{11,12,49,50}, tissue charring or vaporization of the tumour itself that may cause difficulties for the pathologists in identifying the muscle layers. We have used a technique involving the dissection of tissues under direct vision and avoiding excessive burning of tissues, thus reducing the possibility of a false pathological analysis of postoperative samples.

The operative time of ERBT was estimated to be longer and comparable to the TURBT group (44 ± 10.5 min vs. 35 ± 14.5 min). This is due to the slow, precise and efficient incision of ERBT under clear vision, whereas poor visibility of intraoperative bleeding may increase the difficulty of operation and lead to residual tumours^{11,48,51}.

Both ERBT and TURBT techniques may be difficult to carry out in proximal or dome-located tumour resection due to inconvenient resection angle^{7,26,27,52}.

In this case, the protruding tumours can be first superficially retrieved by conventional TURBT, followed by the novel technique to remove the whole tumour including tumour base.

CONCLUSIONS

The „en bloc“ resection of non-muscle invasive bladder tumour proved to be a safe, precise and effective method compared to the conventional resection technique (TURBT). This method provides greater possibilities for obtaining better quality tumour samples, that allow for accurate histopathological

diagnosis and staging, as well as a reduced number of recurrences.

Author Contributions:

Conceptualization, I.V, A.P, A.C, E.C, V.G, G.S; methodology, I.V and V.G.; software, I.V, A.C, A.P; validation, V.G, E.C; formal analysis, V.G, E.C, G.S.; investigation, I.V, A.C, A.P.; resources, I.V, A.C, A.P.; data curation, I.V. and A.C.; writing—original draft preparation, I.V; writing—review and editing, V.G, E.C, G.S.; visualization, V.G.; supervision, E.C and V.G.; project administration, V.G. All the authors have read and agreed with the final version of the article.

Compliance with Ethics Requirements:

„The authors declare no conflict of interest regarding this article“

„The authors declare that all the procedures and experiments of this study respect the ethical standards in the Helsinki Declaration of 1975, as revised in 2008(5), as well as the national law“

„No funding for this study“

Acknowledgments:

None

REFERENCES

1. Adiyat KT, Katkooori D, Soloway CT, De los Santos R, Manoharan M, Soloway MS. Complete transurethral resection of bladder tumors – are the guidelines being followed? *Urology*. 2010;75:365.
2. Chavan S, Bray F, Lortet-Tieulent J, Goodman M, Jemal A. International variations in bladder cancer incidence and mortality. *Eur Urol*. 2014;66:59-73.
3. Epstein JI, Amin MB, Reuter VR, Mostofi FK. The World Health Organization/International Society of Urological Pathology consensus classification of urothelial (transitional cell) neoplasms of the urinary bladder. Bladder Consensus Conference Committee. *Am J Surg Pathol* 1998; 22(12):1435-48.
4. Jemal A, Siegel R, Ward E, Murray T, Xu J, Thun MJ. Cancer statistics 2007. *CA Cancer J Clin*. 2007;57:43-66.
5. Bach T, Muschter R, Herrmann TR, et al. Technical solutions to improve the management of non-muscle-invasive transitional cell carcinoma: Summary of a European Association of Urology Section for Urologic Technology (ESUT) and Section for Urologic Oncology (ESOU) expert meeting and current and future pers. *BJU Int*. 2015;115(1):14-23.
6. Fernandez-Gomez J, Madero R, Solsona E, et al. Predicting non-muscle invasive bladder cancer recurrence and progression in patients treated with bacillus Calmette-Guérin: the CUETO scoring model. *J Urol*. 2009;182:2195-2203.
7. Kramer MW, Wolters M, Herrmann TR. In-block resection of bladder tumors: ready for prime time? *European Urology*. 2016;89(5):967-968.

8. Siegel RL, Miller KD, Jemal A. Cancer statistics. *CA Cancer J Clin.* 2015;65(1):5-29.
9. Burger M, Grossman HB, Droller M, et al. Photodynamic diagnosis of non-muscle-invasive bladder cancer with hexaminolevulinate cystoscopy: a meta-analysis of detection and recurrence based on raw data. *Eur Urol.* 2013;64:846-54.
10. Chung W, Bondaruk J, Jelinek J, et al. Detection of bladder cancer using novel DNA methylation biomarkers in urine sediments. *Cancer Epidemiol Biomarkers Prev.* 2011;20:1483-91.
11. Kamat AM, Witjes JA, Brausi M, et al. Defining and treating the spectrum of intermediate risk non-muscle invasive bladder cancer. *J Urol.* 2014;192:305-15.
12. Holmång S. Follow-up of patients with noninvasive and superficially invasive bladder cancer. *Semin Urol Oncol.* 2000; 18(4):273-279.
13. Millan-Rodriguez F, Chechile-Toniolo G, Salvador-Bayarri J, et al. Primary superficial bladder cancer risk groups according to progression, mortality and recurrence. *J Urol.* 2000;164:680-684.
14. Mitra AP, Datar RH, Cote RJ. Molecular staging of bladder cancer. *BJU Int.* 2005;96:7-12.
15. Buscarini M, Quek ML, Gill P, et al. Molecular prognostic factors in bladder cancer. *BJU Int.* 2005;95:739-742.
16. Chade DC, Shariat SF, Godoy G, Savage CJ, Cronin AM, Bochner BH. Clinical outcomes of primary bladder carcinoma in situ in a contemporary series. *J Urol.* 2010; 184(1):74-80.
17. Lotan Y, Roehrborn CG. Sensitivity and specificity of commonly available bladder tumor markers versus cytology: results of a comprehensive literature review and meta-analysis. *Urology.* 2003;61:109-18.
18. Shadpour P, Emami M, Haghdani S. A comparison of the progression and recurrence risk index in non-muscle-invasive bladder tumors detected by narrow-band imaging versus white light cystoscopy, based on the EORTC Scoring System. *Nephrourol Mon.* 2016;8:e33240.
19. Chatterjee SJ, Datar R, Youssefzadeh D, et al. Combined effects of p53, p21, and pRb expression in the progression of bladder transitional cell carcinoma. *J Clin Oncol.* 2004;22:1007-1013.
20. Dutta SC, Smith JA Jr, Shappell SB, et al. Clinical under staging of high-risk non-muscle invasive urothelial carcinoma treated with radical cystectomy. *J Urol.* 2001;166:490-493.
21. Habuchi T, Marberger M, Droller MJ, et al. Prognostic markers for bladder cancer: International Consensus Panel on bladder tumor markers. *Urology.* 2005;66:64-74.
22. Millan-Rodriguez F, Chechile-Toniolo G, Salvador-Bayarri J, et al. Multivariate analysis of the prognostic factors of primary superficial bladder cancer. *J Urol.* 2000;163:73-78.
23. Reinert T, Modin C, Castano FM, et al. Comprehensive genome methylation analysis in bladder cancer: identification and validation of novel methylated genes and application of these as urinary tumor markers. *Clin Cancer Res.* 2011;17:5582-92.
24. Sylvester RJ, van der Meijden A, Witjes JA, et al. High-grade Ta urothelial carcinoma and carcinoma in situ of the bladder. *Urology.* 2005;66:90-107.
25. Burger M, van der Aa MN, van Oers JM, et al. Prediction of progression of non-muscle-invasive bladder cancer by WHO 1973 and 2004 grading and by FGFR3 mutation status: a prospective study. *Eur Urol.* 2008; 54(4):835-43.
26. Greene FL, Page DL, Fleming ID, et al. *AJCC Cancer Staging Handbook.* 6th ed. New York: Springer; 2002. Urinary bladder; pp. 367-374.
27. National Cancer Institute. Physician Data Query (PDQ). Bladder Cancer Treatment. 2015. Available at <https://www.cancer.gov/types/bladder/hp/bladder-treatment-pdq> (accessed 05 Febr 2020)
28. Pauwels RP, Schapers RF, Smeets AW, et al. Grading in superficial bladder cancer. (1). Morphological criteria. *Br J Urol.* 1988;61:129-134.
29. Schips L, Augustin H, Zigeuner RE, et al. Is repeated transurethral resection justified in patients with newly diagnosed superficial bladder cancer? *Urology.* 2002;59:220-223.
30. Grimm MO, Steinhoff C, Simon X, Spiegelhalder P, Ackermann R, Vogeli TA. Effect of routine repeat transurethral resection for superficial bladder cancer: a long-term observational study. *J Urol.* 2003; 170(2 Pt 1):433-7.
31. Tiglis M, Neagu TP, Elfara M, et al. Nefopam and its role in modulating acute and chronic pain. *Rev Chim.* 2018;69(10):2877-2880.
32. Gontero P, Sylvester R, Pisano F, et al. Prognostic factors and risk groups in T1G3 non-muscle-invasive bladder cancer patients initially treated with Bacillus Calmette-Guerin: results of a retrospective multicenter study of 2451 patients. *Eur Urol.* 2015;67(1):74-82.
33. Masson-Lecomte A, Rava M, Real FX, Hartmann A, Allory Y, Malats N. Inflammatory biomarkers and bladder cancer prognosis: a systematic review. *Eur Urol.* 2014;66:1078-91.
34. Grimm MO, Steinhoff C, Simon X, Spiegelhalder P, Ackermann R, Vogeli TA. Effect of routine repeat transurethral resection for superficial bladder cancer: a long-term observational study. *J Urol.* 2003;170:433-447.
35. Lerner SP, Liu H, Wu M-F, Thomas YK, Witjes JA. Fluorescence and white light cystoscopy for detection of carcinoma in situ of the urinary bladder. *Urol Oncol.* 2012;30:285-9.
36. Smith A, Balar AV, Milowsky MI, Chen RC. Chapter 83: Bladder Cancer. In: Niederhuber J.E., Armitage J.O., Dorshow J.H., Kastan M.B., Tepper J.E., eds. *Abeloff's Clinical Oncology.* 5th ed. Philadelphia, Pa. Elsevier: 2014.
37. Schmitz-Dräger BJ, Droller M, Lokeshwar VB, et al. Molecular markers for bladder cancer screening, early diagnosis, and surveillance: the WHO/ICUD consensus. *Urol Int.* 2015;94:1-24.
38. Golka K, Wiese A, Assennato G, Bolt HM. Occupational exposure and urological cancer. *World J Urol.* 2004;21:382-391.
39. Gudjónsson S. Re: Willem Oosterlinck, Richard Sylvester, Marco Babjuk, et al. Should all patients receive an immediate chemotherapeutic drug instillation after resection of papillary bladder tumors? *Eur Urol.* 2011;59:374-6.
40. Heney NM. Natural history of superficial bladder cancer. Prognostic features and long-term disease course. *Urol Clin North Am.* 1992;19:429-433.
41. Isfoss BL. The sensitivity of fluorescent-light cystoscopy for the detection of carcinoma in situ (CIS) of the bladder: a meta-analysis with comments on gold standard. *BJU Int.* 2011;108:1703-7.
42. Chou R, Gore JL, Buckley D, et al. Urinary biomarkers for diagnosis of bladder cancer: a systematic review and meta-analysis. *Ann Intern Med.* 2015;163:922-31.
43. Iorga L, Anghel R, Marcu D, et al. Renal sarcoma - a rare parenchymal tumor with a very poor prognosis. *Arch Balk Med Union.* 2018;53(3):434-438.
44. Jain A, Phillips RM, Scally AJ, Lenaz G, Beer M, Puri R. Response of multiple recurrent TaT1 bladder cancer to

- intravesical apaziquone (EO9): comparative analysis of tumor recurrence rates. *Urology*. 2009;73: 1083-1086.
45. Jakse G, Hall R, Bono A, et al. Intravesical BCG in patients with carcinoma in situ of the urinary bladder: long-term results of EORTC GU Group phase II protocol 30861. *Eur Urol*. 2001;40:144-150.
 46. Lamm D, Persad R, Brausi M, et al. Defining progression in non-muscle invasive bladder cancer: it is time for a new, standard definition. *J Urol*. 2014;191:20-7.
 47. Kantor AF, Hartge P, Hoover RN, et al. Urinary tract infection and risk of bladder cancer. *Am J Epidemiol*. 1984;119:510-515.
 48. Torre LA, Bray F, Siegel RL, Ferlay J, Lortet-Tieulent J, Jemal A. Global cancer statistics, 2012. *CA Cancer J Clin*. 2015;65:87-108.
 49. Jemal A, Murray T, Ward E, et al. Cancer statistics, 2005. *CA Cancer J Clin*. 2005; 55(1):10-30.
 50. Lebre T, Bohin D, Kassardjian Z, et al. Recurrence, progression and success in stage Ta grade 3 bladder tumors treated with low dose bacillus Calmette-Guérin instillations. *J Urol*. 2000;163:63-67.
 51. Jebar AH, Hurst CD, Tomlinson DC, et al. FGFR3 and Ras gene mutations are mutually exclusive genetic events in urothelial cell carcinoma. *Oncogene*. 2005;24:5218-5225.
 52. Kulkarni GS, Hakenberg OW, Gschwend JE, Thalmann G, Kassouf W, Kamat A. An updated critical analysis of the treatment strategy for newly diagnosed high-grade T1 (previously T1G3) bladder cancer. *Eur Urol*. 2010;57(1):60-70.