

CASE REPORT

TYMPANOJUGULAR PARAGANGLIOMAS. TWO CASE REPORTS

Raluca GRIGORE^{1,2}, Anca I. CIRSTEANU¹✉, Paula BEJENARU¹, Catrinel B. SIMION-ANTONIE¹,
Gloria S. MUNTEANU¹, Alexandru NICOLAESCU^{2,3}, Mihnea CONDEESCU-COJOCARITA^{1,2},
Serban V.G. BERTESTEANU^{1,2}

¹ENT Department, Coltea Clinical Hospital, Bucharest, Romania

²University of Medicine and Pharmacy „Carol Davila“, Bucharest, Romania

³Emergency Hospital of the Ministry of Internal Affairs „Prof. Dr. Dimitrie Gerota“, Bucharest, Romania

Received 02 May 2020, Accepted 14 May 2020

<https://doi.org/10.31688/ABMU.2020.55.2.20>

ABSTRACT

Introduction. Paragangliomas are benign tumours that arise from the paraganglionic system. The most frequently encountered symptoms of tympanojugular paragangliomas are pulsatile tinnitus and conductive hearing loss. High resolution computed tomography, with reconstruction in axial and coronal planes, is mandatory in every suspected case of tympanojugular paraganglioma. The treatment is guided by the classification of Fish.

Cases presentation. We present two cases in whom the clinical manifestations and paraclinical investigations established the diagnosis of tympanojugular paraganglioma. Both surgery and postoperative evolution are described for each case. In most of these tumours, surgery remains the mainstay treatment. According to the preoperative plan of the first case, it was decided that the tumour can be resected safely, without compromising the cranial nerves. In the second case, the entire tumour was removed, but with the sacrifice of the inferior cranial nerve, caught in the tumour mass.

Conclusions. These tumours have the tendency to involve multiple vital structures of the skull base. A

RÉSUMÉ

Les paragangliomes tympaniques-jugulaires – Rapports de deux cas

Introduction. Les paragangliomes sont des tumeurs bénignes qui proviennent du système paraganglionnaire. Les symptômes les plus fréquemment rencontrés pour les paragangliomes tympaniques-jugulaires sont les acouphènes pulsatiles et la perte auditive conductrice. La tomographie à haute résolution, avec reconstruction dans les plans axial et coronal, est obligatoire dans chaque cas soupçonné de paragangliome tympanique-jugulaire. Le traitement est guidé par la classification de Fish.

Présentation des cas. Les auteurs présentent deux cas de femmes, pour lesquels les manifestations cliniques et l'enquête paraclinique ont établi le diagnostic de paragangliome tympanique-jugulaire. La chirurgie et l'évolution postopératoire seront décrites pour chaque cas. Dans la majorité de ces tumeurs, la chirurgie reste le pilier du traitement. Suivant le plan préopératoire du premier cas, il a été décidé que la tumeur pouvait être réséquée en toute sécurité sans

✉ Address for correspondence:

Anca I. CIRSTEANU

„Coltea“ Clinical Hospital, Bucharest, Romania

Address: „Ion C. Bratianu“ Blvd no.1, Bucharest, Romania

Emails: cirsteanaaa@gmail.com, raluca.grigore@3f.ro, berstein@dr.com

detailed preoperative plan of treatment is required to maximize tumour resection, while minimizing morbidity of the great vessels and lower cranial nerves.

Keywords: tympanojugular, paraganglioma, skull base.

List of abbreviations:

TMP = tympanomastoid paragangliomas;
TJP = tympanojugular paragangliomas;
VMA = vanillylmandelic acid;
CT = computed tomography;
MRI = magnetic resonance imaging;
SCM = sternocleidomastoid

INTRODUCTION

Paragangliomas are vascular tumours that arise from the paraganglionic system, also called glomus tumours, nonchromaffin tumours or chemodectomas. The paraganglionic system represents the aggregation of cells found throughout the body, associated with vascular and neuronal adventitia. They are benign tumours, but 10% of them can metastasize¹.

Head and neck glomus tumours can be divided into tympanojugular and cervicocarotid. The cervical-carotid glomus tumours can be vagal or carotid body tumours. Another 20 sites in the head and neck region have been identified, but they are very rare¹.

Tympanojugular paragangliomas (TJP) arise in the adventitia of the jugular bulb or along the course of the Jacobson nerve (which is the tympanic branch of the glossopharyngeal nerve) or the Arnold nerve (that is the auricular branch of the vagal nerve)². There are 2 types of TJP. The first one is the tympanic or tympanic mastoid paraganglioma (TMP), in this case the tumour is placed in the middle ear and mastoid system, usually without local invasion. The second one, tympanojugular proper glomus, describes a paraganglioma involving both jugular foramen and middle ear cavity, this type of tumour being more aggressive.

The clinical presentation depends on the site of the tumour. For both TMP and TJP, the most frequently encountered symptoms are pulsatile tinnitus and conductive hearing loss. In the case of TMP, we also can find a retro tympanic reddish mass, otalgia, ear fulness and otorrhea, while in the case of TJP we can find sensorineural hearing loss/vestibular symptoms, facial and lower cranial nerve palsy³.

Diagnosis is based on inspection and palpation of the neck, inspection of the oral cavity and pharyngo-larynx for lower cranial nerve involvement, otoscopy (pulsatile retro tympanic vascular mass, known

compromettre les nerfs crâniens. Dans notre deuxième cas, la tumeur entière a été enlevée, mais avec le sacrifice du nerf crânien inférieur compromis, étant attaché à la masse tumorale.

Conclusions. Ces tumeurs ont tendance à impliquer plusieurs structures vitales de la base du crâne. Un plan de traitement préopératoire détaillé est nécessaire pour maximiser la résection tumorale tout en minimisant la morbidité des gros vaisseaux et des nerfs crâniens inférieurs.

Mots-clés: tympanique-jugulaire, paragangliome, base du crâne.

as Brown's sign), audio-vestibular testing, imaging, catecholamine secretion and radionuclide scintigraphy for the detection of multicentric or metastatic lesions in familiar tumours^{4,5}. The imaging options for the diagnosis of glomus tumours are: high-resolution computed tomography (CT), with reconstruction in axial and coronal planes, to define the extent of involvement of the temporal bone, high-resolution magnetic resonance imaging (MRI) to characterize the vascular nature of the tumour ("salt and pepper" aspect), magnetic resonance angiography and venography for the jugular foramen involvement^{6,7}.

Treatment is guided by the classification of Fish⁸. The options are to cure the disease, to control it or palliation. The best choice is the total surgical removal, with or without preoperative embolization. This option is possible more often in the cases of TMP. Other options include subtotal removal, with or without postoperative radiotherapy, partial resection for symptomatic control or primary radiotherapy⁹. The „wait and scan“ policy is used for asymptomatic patients¹⁰.

In this article, we present two cases of female patients, who presented for hearing loss in the ENT clinic, Coltea Clinical Hospital, Bucharest, Romania. The clinical manifestations, the methods of diagnosis and treatment will also be described.

FIRST CASE PRESENTATION

A 68-year-old female patient, living in rural area, presented to the ENT Clinic of Coltea Clinical Hospital, Bucharest, Romania, for hearing loss and tinnitus, that started 5 years ago and gradually got worse. The patient's past medical history includes type II diabetes, hypertension, stroke (10 years ago), bronchial asthma and betalactam allergy.

Clinical examination of the head and neck region revealed a left latero-cervical tumoural mass, 5/6

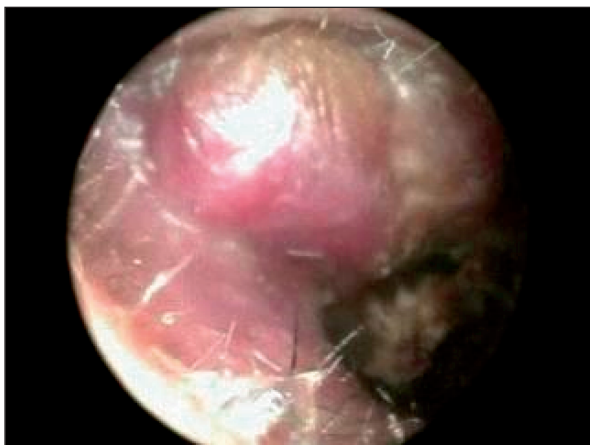

Figure 1. Retro-tympanic vascular mass.

centimeters in diameter, with soft consistency, mobile on the superficial layers, but immobile on the deep layers, with superior extension to the retromandibular region.

The otoscopic examination revealed a pulsatile retro-tympanic vascular mass (Figure 1). An audiogram was also performed, which showed mixed hearing loss, with predominance of transmission on the left ear. Neurological exam was normal. The vanillyl-mandelic acid (VMA) urinary level was also normal.

Head and neck CT scan were performed and revealed a solid tumour, intense iodophilic, 4/3 centimeters in diameter, with nodular calcifications at the level of the internal jugular vein. The tumour invades and destroys the tip of the temporal bone and the bony structures of the left inner ear. It also invades the left pontocerebellar angle (Figure 2).

The angiography showed a left latero-cervical hyper vascular tumour, 5/3 centimeters in diameter,

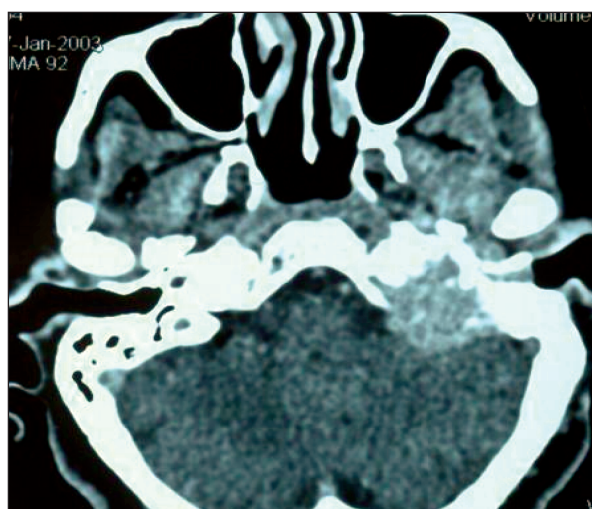

Figure 2. CT scan – solid tumour at the left pontocerebellar angle

with the caudal limit at the level of the third cervical vertebra, vascularized by branches of the common internal and external left carotid artery (Figure 3). The venous drainage in the left jugular vein had a 50% stenosis at the third cervical vertebra level.

The differential diagnosis of the glomus tumours is made with aberrant carotid artery, intrapetrous carotid artery aneurysm, lower cranial nerve Schwannomas, jugular foramen meningiomas, jugular bulb anomalies, jugular foramen chondrosarcomas, endolymphatic sac tumours⁵.

In this case, the positive diagnosis was glomus tumour of the internal jugular vein, class D, extradural, according to Fish's classification.

The therapy plan was decided to be radical surgery with curative intent, followed by radiotherapy. The surgery was performed under general anesthesia and started with an incision at the anterior edge of the left sternocleidomastoid (SCM) muscle, with the exposure of the neck's major arteries and veins. The incision was then extended retro auricular. The mastoid was drilled and the left lateral sinus was highlighted. The lateral sinus was ligated in the proximal portion. The internal jugular vein was also ligated. The tumour was removed at the level of the jugular gulf and included a total petromastoid eviderment. The petromastoid cavity was meshed and an external auditory canal plasty was performed.

The post-surgical recovery was favorable and the neurological exam was still normal. The histopathological examination (Figure 4) revealed a paraganglioma with polyhedral epithelial cells arranged in cords, clear cytoplasm, large, central nucleus.

The patient underwent adjuvant therapy post-surgery with 30 sessions of radiotherapy.

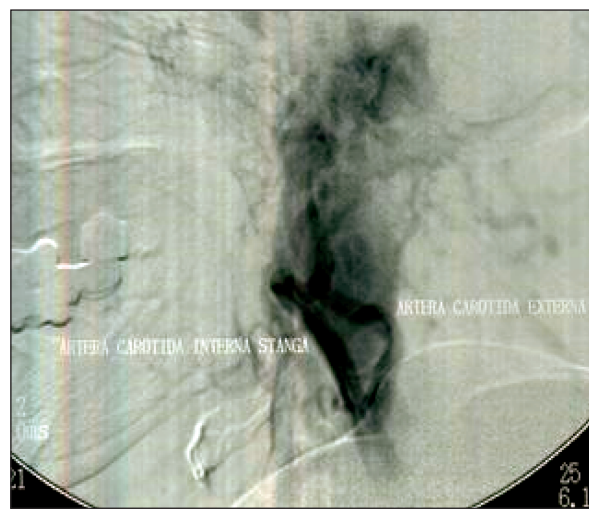


Figure 3. Angiography–hyper vascular tumour

SECOND CASE PRESENTATION

A 32-year-old female living in the urban area, presented to the ENT Clinic of Coltea Clinical Hospital, Bucharest, Romania, with a 6 months history of right ear pulsatile tinnitus, hearing loss and right facial paralysis.

The clinical examination of the head and neck region revealed facial asymmetry due to the impossibility of closing the right eye, with widening of the eyelid slit, inability to perform movements with the orbicularis muscle of the right side lips and right sided face paresthesia.

The otoscopic examination revealed a reddish (“sun rise lesion”), posterosuperior retrotympanic mass at the surface area of the pars flaccida (Figure 5). The tympanic membrane was moving synchronously with the pulse. The audiogram revealed severe mixed eight ear hearing loss.

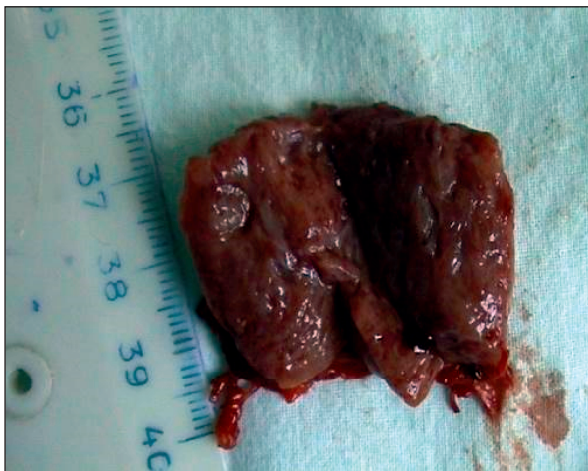

Figure 4. Excision piece.

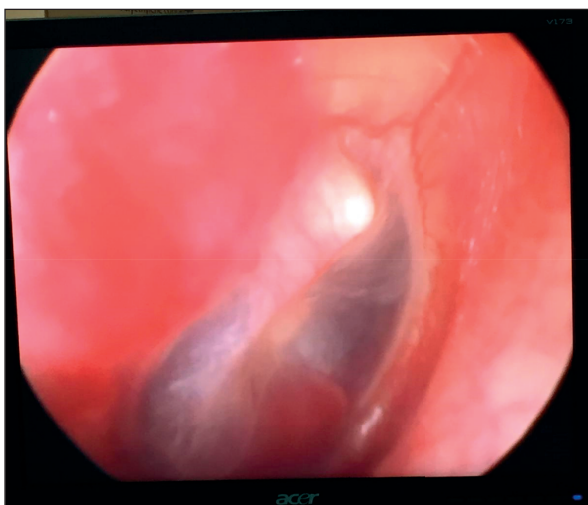


Figure 5. Sun rise sign

An MRI of the head and neck region was performed and revealed a tumour mass, with maximum axial dimensions of about 35/22 mm and 30 mm craniocaudal, relatively well demarcated, located in the right pontocerebellar angle, with mastoid invasion (bone lysis) and inclusion of the right internal auditory canal and the VII and VIII nerves, with anterior extension to the level of right internal carotid artery and caudal to the level of the jugular vein, with intensely homogenous gadophilia – intensely vascularized (Figure 6).

An angiography was performed, too, and it revealed a ride-sided hyper vascular tumour (Figure 7). Based on the clinical and paraclinical investigations, the diagnosis of right tympanojugular paraganglioma class C2 was established. Due to the extension and neurological damage, the patient was redirected to another center, where surgery could be performed by a multidisciplinary team of surgeons and neurosurgeons.

A preoperative paraganglioma embolization was performed. The surgical intervention consisted in removing the tumour part from the extradural level and from the external auditory canal (Figure 8). Facial nerve reconstruction was performed. The surgical cavity was obliterated with abdominal fat. Subsequently, the patient underwent a lateral tarsorrhaphy procedure. In the postoperative period, the patient developed facial nerve palsy (Figure 9) and also lower right cranial nerves palsy. At a distance, a good pharyngeal compensation was obtained.

DISCUSSION

Despite of the fact that paragangliomas are benign tumours, they show increased aggressiveness

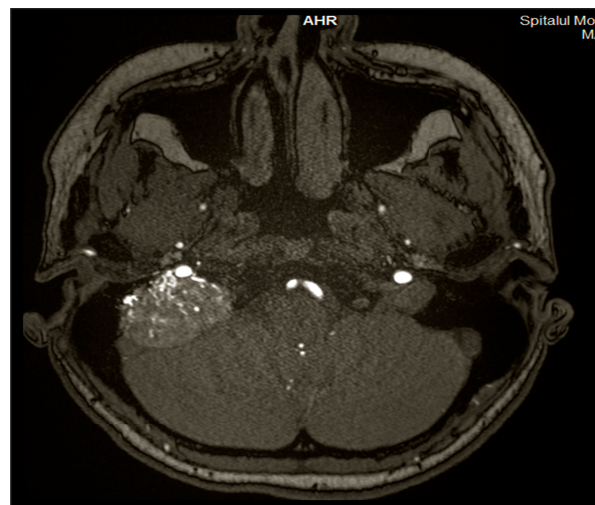


Figure 6. MRI scan – tumour mass at the right pontocerebellar angle

through their extension. The right treatment of these types of tumours is debated in the literature. For most of these tumours, surgery remains the main treatment. Relative contraindications to surgery include extensive skull-base or intracranial involvement, advanced age of the patient, medical comorbidities, and bilateral or multiple paragangliomas, which may result in unacceptable postoperative morbidity and bilateral lower cranial nerve palsies^{4,11,12}.

Resection of paragangliomas of the temporal bone is linked to their extension and it is according to Fish's classification⁸:

- Class A: tumour limited to middle ear (glomus tympanicum).
- Class B: tumour limited to the tympanomastoid area with no infra labyrinthine involvement (glomus hypo tympanicum).
- Class C: tumours involving the infra labyrinthine compartment of the temporal bone and extending into the petrous apex.
- Class De: tumours with intracranial extradural extension.
- Class Di: tumours with intracranial intradural extension.

The goal for the TMP is the gross total removal. There is no role for radiotherapy. For elderly patients with class B, the „wait and scan“ policy or a subtotal removal can be used. The surgery indicated for class

A is the trans canal approach. For class B, the best choice is the mastoid-extended facial recess approach. Infratemporal fossa approach, with rerouting of the facial nerve, is proposed for classes C and D^{13,14}.

In the case of TJP, in young patients with normal cranial nerve function, surgery can be performed. The incidence of lower cranial nerve deficit is higher in class C and D tumour resection. If there is a low possibility of neural preservation, we can allow the tumour to gradually paralyze the lower cranial nerves

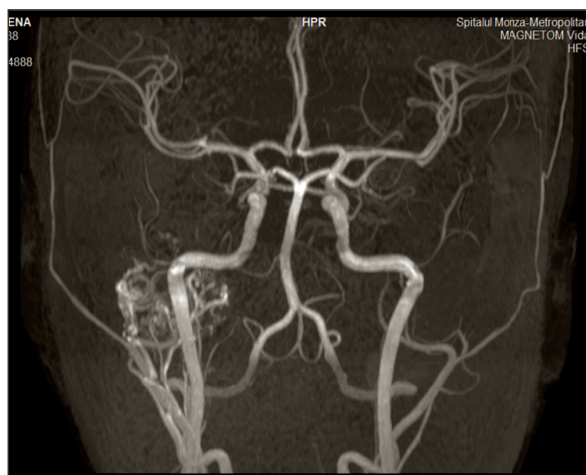

Figure 7. Angiography – hyper vascular tumour on the right side

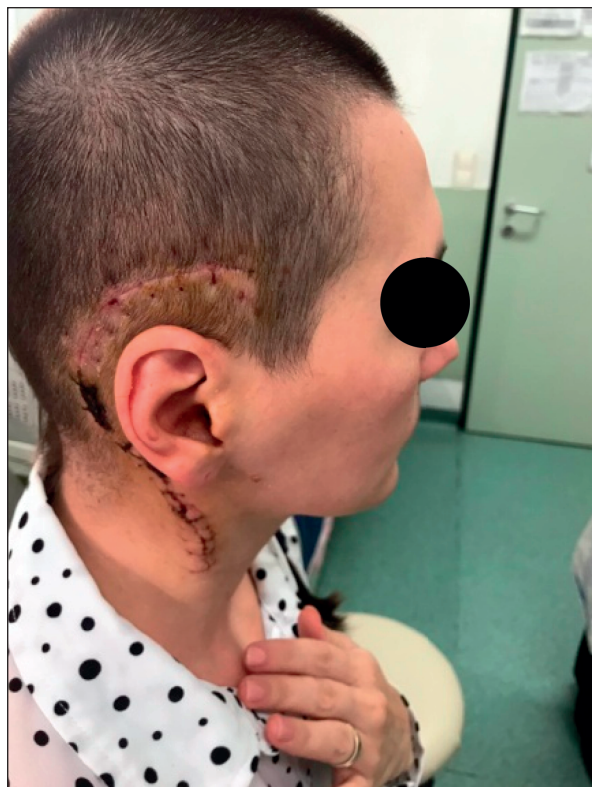

Figure 8. Postoperative scar

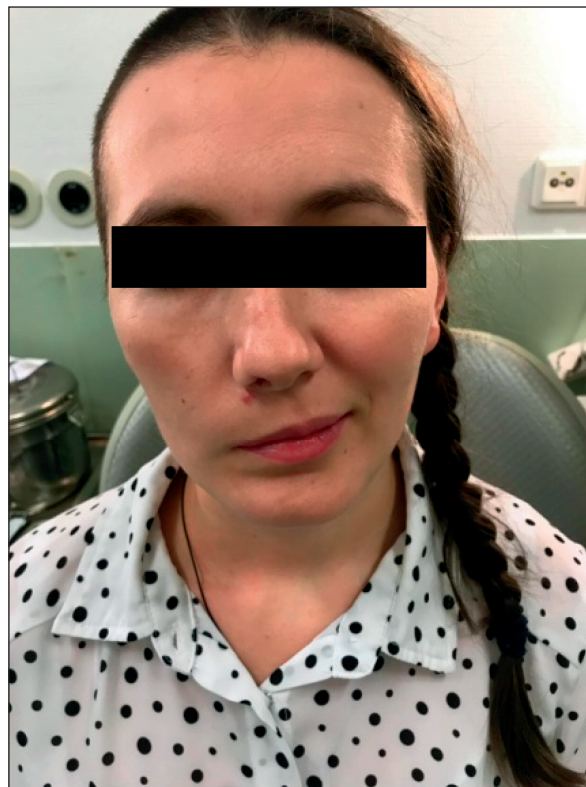

Figure 9. Postoperative facial paralysis

and after the compensation appears, we can perform surgery^{9,15}. In our second case, the entire tumour was removed, but with the sacrifice of inferior cranial nerve, being caught inside the tumour mass. Usually, compensation following acute compound lower cranial nerve palsies is good in young patients, as it happened in our second case.

For elderly patients with normal cranial nerve function, we can proceed to radiological follow up and if a significant growth is documented, the patient has to start radiotherapy¹³.

The patient's choice is very important when a decision is made. Our first patient has chosen surgery. Despite tumour extension (class D), the facial nerve was kept in anatomical position and facial nerve function was normal during the immediate postoperative period. Other cases are described in the literature, in which complete tumour resection was performed, without anterior transposition of the facial nerve. The extension of dissection should be tailored to each case, based on tumour blood supply, pre-operative symptoms, and tumour extension¹⁶.

Although the second case had a better prognosis due to the smaller tumour extension, compared to the first case, damage to the cranial nerves, and especially the facial nerve following tumour resection, was much more important. Therefore, further studies are needed to address tumour extension relative to the facial nerve, not just temporal bone extension.

CONCLUSIONS

The assessment and management of head and neck paragangliomas remain a demanding task, due to the complex anatomical relationships at the skull base. Based on proper preoperative assessment, a detailed, systematic plan of treatment is required in order to remove the tumour while minimizing morbidity of the great vessels and lower cranial nerves.

Author Contributions:

R.G. and S.V.B.G. were responsible for the diagnostic procedures, clinical diagnosis, and treatment decisions. A.I.C., P.B., C.B.S.A., G.S.M., A.N., M.C.C. wrote the manuscript. All authors have read and agreed to the published version of the manuscript.

Compliance with Ethics Requirements:

„The authors declare no conflict of interest regarding this article“

„The authors declare that all the procedures and experiments of this study respect the ethical standards in the

Helsinki Declaration of 1975, as revised in 2008(5), as well as the national law. Informed consent was obtained from the patients included in the study“

„No funding for this study“

Acknowledgements:

None

REFERENCES

1. Williams MD. Paragangliomas of the head and neck: an overview from diagnosis to genetics. *Head and Neck Pathology* 2017;11(3):278-287.
2. Lee JC, Malhotra A, Wang H, Westesson PL. Paragangliomas of the head and neck: a pictorial essay. *URMC Radiology*. 2007;1-25.
3. Prasad SC, Paties CT, Schiavi F, et al. Tympanojugular paragangliomas: surgical management and clinicopathological features. Paraganglioma: a multidisciplinary approach . Brisbane (AU): Codon Publications; 2019.
4. Persky MS, Hu KS. Paragangliomas of the head and neck. *Head and Neck Cancer: A Multidisciplinary Approach*. 3rd ed. Lippincott Williams and Wilkins, Philadelphia, PA; 2009 .
5. Anniko M, Bernal-Sprekelsen M, Bonkowsky V, Bradley P, Iurato S. Otorhinolaryngology. *Head & Neck Surgery. Paragangliomas of the temporal bone*. Springer, 2010: 97-100.
6. Van den Berg R, Verbist BM, Mertens BJ, van der Mey AG, van Buchen MA. Head and neck paragangliomas: improved tumor detections using contrast-enhanced 3D time-of-flight MR angiography, as compared with fat-suppressed MR imaging techniques. *Am J Neuroradiol*. 2004;25(5):863-70.
7. Axmann C, Dorenbeck U, Reith W. Glomus tumor en der kopfhals-region. *Radiologe*. 2004; 44:389-400.
8. Fisch U. Infratemporal fossa approach for glomus tumors of the temporal bone. *Ann Otol Rhinol Laryngol*. 1982;91:474-479.
9. Sanna M, Piazza P, Shin SH. Microsurgery of skull base paragangliomas. Thieme, 2013
10. Mendenhall WM, Amdur RJ, Vaysberg M, et al. Head and neck paragangliomas. *Head Neck*. 2011;33:1530-1534.
11. Diaconu CC, Dediu GN, Iancu MA. Drug-induced arterial hypertension, a frequently ignored cause of secondary hypertension: a review. *Acta Cardiologica*. 2018;73(6):511-517.
12. Dediu G, Dumitrache Rujinski S, Lungu R, et al. Positive pressure therapy in patients with cardiac arrhythmias and obstructive sleep apnea. *Pneumologia*. 2015;64(1):18-22.
13. Cosetti M, Linstrom C, Alexiades G, Tessema B, Parisier S. Triological Society Annual Meeting, San Diego, California, U.S.A. April 29, 2007.
14. Jackson CG. Surgery of skull base tumors. Churchill Livingstone; 1991.
15. Tiglis M, Neagu TP, Elfara M, et al. Nefopam and its role in modulating acute and chronic pain. *Rev Chim*. 2018;69(10):2877-2880.
16. Borba L, Araújo J, de Oliveira J, et al. Surgical management of glomus jugular tumors: a proposal for approach selection based on tumor relationships with the facial nerve. *Journal of Neurosurgery*. 2009;112:88-98.