

## CASE REPORT

# TOTAL LARYNGECTOMY WITH VOICE PROSTHESIS – „GOLD STANDARD“ TREATMENT FOR PATIENTS WITH ADVANCED LARYNGEAL CANCER

Mihail TUSALIU<sup>1,2✉</sup>, Iulia TITA<sup>1</sup>, Diana TUAS<sup>1</sup>, Ruxandra RANETE<sup>1</sup>, Cristina GOANTA<sup>1,3</sup>

<sup>1</sup> „Prof. Dr. D. Hociota“ Institute of Phonoaudiology and Functional ENT Surgery, Bucharest, Romania

<sup>2</sup> „Carol Davila“ University of Medicine and Pharmacy, Bucharest, Romania

<sup>3</sup> Clinical Hospital „Colentina“, Bucharest, Romania

Received 26 July 2020, Accepted 15 Aug 2020

<https://doi.org/10.31688/ABMU.2020.55.3.22>

### ABSTRACT

**Introduction.** The aim of this article is to present the advantages of tracheoesophageal puncture using secondary placement of the voice prosthesis, at present the „gold standard“ for voice rehabilitation in the laryngectomized patient with advanced cancer following total laryngectomy. Absence of voice and, therefore, inability to verbally communicate, constitutes one of the greatest challenges for laryngeal cancer patients, having a major impact on their quality of life.

**Case report.** The authors illustrate the case of a 61-year-old patient diagnosed with advanced laryngeal cancer, who underwent total laryngectomy. After approximately one year, a voice prosthesis is installed. Phonation was immediate and close to natural laryngeal speech.

**Conclusions.** From a functional, as well as psychological and social point of view, a laryngeal cancer diagnosis can have devastating consequences on all aspects of a patient's life. Phonation recovery is thus essential for psychological well-being, labour and social reintegration. Correct understanding and management of this pathology and treatment options is of utmost

### RÉSUMÉ

**Laryngectomie total avec prothèse vocale – le standard d'or pour les patients avec du cancer laryngien avancé**

**Introduction.** Le but de cet article est de présenter les avantages de la ponction trachéale-œsophagienne par la mise en place secondaire de la prothèse vocale, considérée le « standard d'or » de la rééducation vocale pour le patient laryngectomisé avec un cancer avancé suite à la laryngectomie totale. L'absence de la voix et, par conséquent, l'incapacité de communiquer verbalement, constitue l'un des plus grands défis pour les patients diagnostiqués avec un cancer du larynx, ayant un impact majeur sur la qualité de vie.

**Cas clinique.** Les auteurs présentent le cas d'un patient de 61 ans diagnostiqué avec un cancer du larynx avancé, qui a subi une laryngectomie totale. Après environ un an, une prothèse vocale est utilisée. La phonation a été immédiate et proche de la parole naturelle du larynx.

**Conclusions.** D'un point de vue fonctionnel, mais aussi psychologique et social, le diagnostic de cancer

✉ Address for correspondence:

Mihail TUSALIU  
„Prof. Dr. D. Hociota“ Institute of Phonoaudiology and Functional ENT  
Surgery, Bucharest, Romania  
Address: Mihail Cioranu Str, no. 21, Bucharest, 061344 Romania  
E-mail: mtusaliu@yahoo.com; Phone: (+40)729828480

importance in obtaining the best possible medium and long-term outcomes. Secondary placement of the voice prosthesis provides greater oncological safety as well as avoids common post-radiotherapy side effects.

**Keywords:** advanced laryngeal cancer, voice prosthesis, total laryngectomy.

## INTRODUCTION

Laryngeal cancer is the most common malignancy of the upper aerodigestive tract. With over 135,000 newly diagnosed cases and 80,000 deaths annually, it has a growing global incidence<sup>1</sup> due to increased exposure to risk factors, such as: smoking, chronic ethanol use, viral infections (mainly human papillomavirus) and occupational exposure to various types of toxins<sup>2,3</sup>.

Conservative treatment options, including organ-preservation surgery, radiotherapy, chemotherapy or concurrent chemoradiotherapy, may be considered suitable when diagnosis takes place at an early stage of the disease. Surgical techniques used in treating laryngeal cancer fall into two broad categories: partial laryngectomy, involving resection of a portion of the larynx, while keeping in place the unaffected structures, and total interventions. However, in advanced-stage laryngeal cancer, total laryngectomy is the preferred option<sup>4</sup>.

Speech rehabilitation following total laryngectomy may currently be achieved through any of three available voice restoration options: electrolarynx, esophageal speech and tracheoesophageal speech. The latter, first described by Guttman in 1932, requires creating a tracheoesophageal puncture between the posterior wall of the tracheostome and the upper esophagus. A silicone prosthesis is then inserted. The first reliable silicone voice prosthesis was introduced in 1979 by Eric Blom and Mark Singer. This acts as a unidirectional valve, opening to allow normal breathing, but at the same time preventing aspiration of food and fluids. Exhaled tracheal air is pushed into the vibratory segment of the pharynx during exhaling. This allows speech to be formed by articulating the sound thus produced using the tongue, teeth and lips<sup>5,6</sup>.

While, over the years, there has been a progress in both the surgical techniques, as well as the design of the prosthesis itself, the underlying principle

du larynx peut avoir des conséquences dévastatrices sur tous les aspects de la vie d'un patient. La récupération de la phonation est donc essentielle pour le bien-être psychologique, le travail et la réinsertion sociale. Une compréhension et une gestion correcte de cette pathologie et des options de traitement ont une grande importance pour obtenir les meilleurs résultats possibles à moyen et long-terme. Le placement secondaire de la prothèse vocale offre une plus grande sécurité oncologique et évite les effets secondaires ordinaires postradiothérapie.

**Mots-clés:** cancer du larynx, prothèse vocale, laryngectomie totale.

remains the same to this today. Phonation is immediate, sustained and closer to laryngeal speech compared to other options.


The success rate of tracheoesophageal speech following total laryngectomy varies between 70-95%<sup>6</sup>. Successful voice restoration may be influenced by factors such as: size and loco-regional extension of the tumour, extent of remaining pharyngeal mucosa after resection, presence of underlying health conditions like obesity, damage to cervical tissues after irradiation therapy, patient's ability to individually operate and properly maintain the prosthesis, in order to avoid obstruction and prolong the life of the device<sup>7</sup>.

The installation of the voice prosthesis may be performed as a primary procedure, at the time of total laryngectomy, or at a later stage following completion of the oncological treatment, as a secondary procedure. While originally developed as a secondary procedure, since 1985, when Hamaker et al incorporated it into the total laryngectomy, primary tracheoesophageal puncture offered the advantage of avoiding a secondary intervention. However, phonation recovery is delayed by local edema, clots or secretion immediately following oncological treatment – all of which may cause device malfunction<sup>8,9</sup> (Fig. 1).

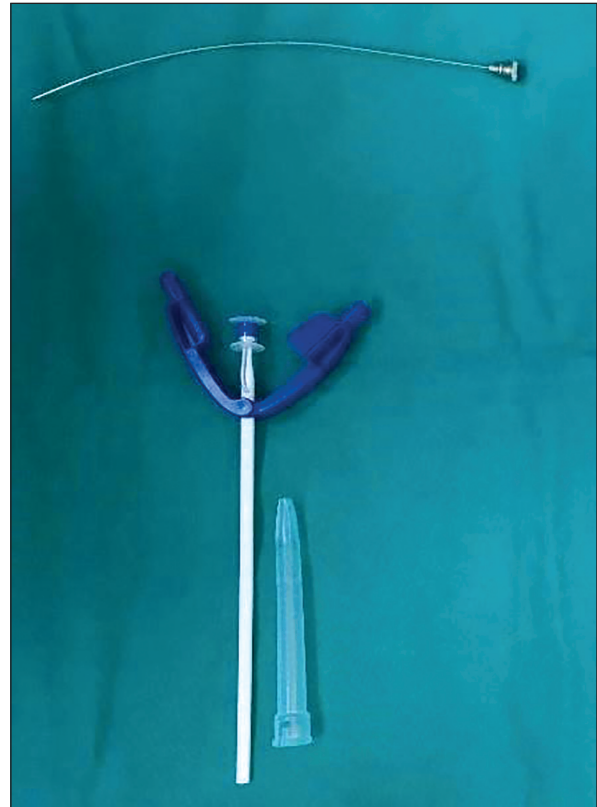Secondary placement of the voice prosthesis is performed after surgery and about six months following completion of cancer treatment. Thus, it may prove superior compared to primary placement in the short and medium term, providing greater oncological safety by allowing for a more generous time frame, as well as avoiding common post-radiotherapy site issues, since at time of placement edema is greatly diminished or even absent<sup>10</sup> (Fig. 2).

## CASE REPORT

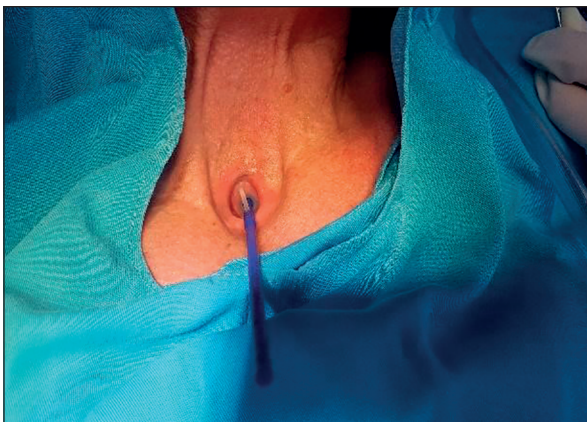
We present the clinical case of a 61-year-old male, former smoker, admitted for dysphagia, dysphonia



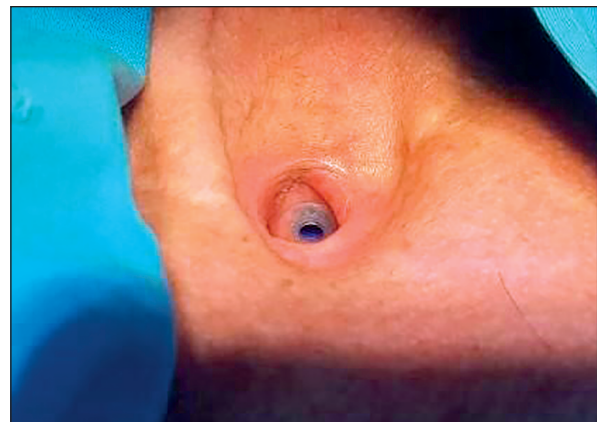
**Fig. 1.** Voice prosthesis – secondary puncture.



**Fig. 2.** Voice prosthesis – replacement procedure.



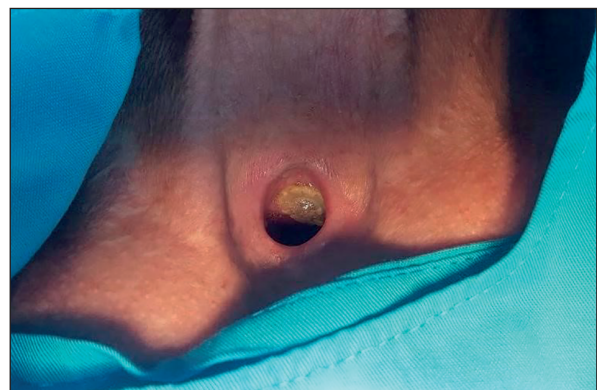**Fig. 3.** Voice prosthesis during insertion.



**Fig. 4.** Voice prosthesis after insertion.

and sudden weight loss. Clinical ENT examination and laryngeal endoscopy showed an infiltrative tumor including the anterior and posterior commissure together with subglottic extension. The biopsy showed G1 well-differentiated keratinizing spinocellular epidermoid carcinoma.

Once diagnosed with advanced laryngeal cancer, the patient consented to and successfully underwent a systematic, step by step, total laryngectomy with partial pharyngotomy and neck lymph node dissection. Biopptic fragments were sent to histopathological examination and immunohistochemical tests,



**Fig. 5.** Deteriorated voice prosthesis.

confirming the diagnosis. The aim was to obtain the best possible medium and long-term results, therefore multidisciplinary treatment was needed: surgical treatment followed by 30 sessions of radiation therapy. Further clinical and endoscopic ENT evaluation showed no macroscopic signs of cancer recurrence.

Treatment should take into account voice rehabilitation with the goal of obtaining a sound voice and the ability to speak. Nowadays, the golden standard for patients with advanced laryngeal cancer is total laryngectomy with voice prosthesis. In our case, one year after surgical and oncological treatment, when post-radiotherapy edema and late postoperative complications were absent, we opted for secondary vocal rehabilitation with Provox VEGA 8 mm under local anesthesia. The patient showed favorable general and local evolution with immediate phonation. Subsequently, we decided to replace the voice prosthesis every 6 months up to 1 year, depending on the quality of the device and patient's preference (Fig. 3, 4).

## DISCUSSION

From a functional, as well as psychological and social point of view, the laryngeal cancer diagnosis can have devastating consequences on all aspects of a patient's life. Speech, swallow and breath are fundamental functions of the larynx, thus, despite ensuring good oncological outcomes in many loco-regionally advanced cases, ablative surgery is associated with significant disabling consequences.

Post-surgery quality of life correlates with patient's survival. That is why modern oncology takes it into account when evaluating the consequences of head and neck cancer treatment. While inevitable and permanent aphonia is not the only factor reducing patients' quality of life, it may uniquely result in social stigma and lifelong psychological sequelae, including altered self-image, anxiety, depression and social isolation. Phonation recovery is thus essential for psychological well-being, labour and social reintegration.

A number of devices are available – such as Blom-Singer, Provox 1 and 2, Groningen, Voice Master, Nijdam and Bordeaux – with manufacturers greatly improving and expanding their ranges, from hands-free valves – such as Blom-Singer or Provox FreeHands Heat and Moisture Exchanger, to fungal-resistant valves, prostheses have been developed in recent years to provide low airflow resistance, optimal retention, prolonged device lifespan, simple maintenance and comfortable replacement. Automatic valves, however, are associated with harder breathing compared to regular, digital systems<sup>11,12</sup>.

Provox, first introduced in 1990 by the Department of Otolaryngology of the Netherlands

Cancer Institute, has gained popularity, becoming one of the most widely used. The second generation, Provox 2, allows for a more comfortable outpatient replacement, using an anterograde replacement technique.

All prostheses are, eventually, confronted with deterioration, therefore troubleshooting should be anticipated, and, ultimately and inevitably, dysfunction and replacement. Leakage through the valve is the most common maintenance issue, as well as the most common indicator for valve replacement. Usually, this is due to normal wear and tear. However, to determine the precise cause of leakage, careful observation should be conducted, both in situ as well as inspecting the valves after removal. Leakage through the valve may be due to a curled or deformed appearance which may have occurred during insertion, or movement of the flap valve in conjunction with the patient's swallowing or respiratory pattern – usually indicative of negative pressure in the esophagus sucking the flap valve open<sup>13</sup>.

Microbial colonization of silicon material may also cause leakage through the valve. The presence of *Candida* deposits interfering with proper seating of the valve may be considered the most important factor determining prosthesis lifespan. While antifungal treatment can prolong the device's life, long-term use of antimicrobials may lead to resistant strains<sup>14</sup> (Fig. 5).

Leakage around the valve is the second most common indicator for valve replacement and is usually caused by an enlarged tracheoesophageal fistula, tumour recurrence or a failure of the wound to heal due to tissue necrosis following radiation.

Other reported maintenance issues include: extrusion of the valve from the tracheoesophageal tract may occur during cleaning or coughing – if the valve is not replaced immediately, stenosis of the tract will occur, resulting in closure of the puncture site; formation of a thick fibrous tissue ring around the prosthesis, lengthening the tract and drawing the posterior end of the valve forward into the tract; as high as 82% of laryngectomized patients reported experiencing gastroesophageal reflux disease, that could lead to valve failure<sup>15</sup>.

Patients may also experience a weak, breathy voice as a result of a flaccid pharyngoesophageal segment, causing constrictor hypotonicity; granulation tissue formation as a result of trauma or irritation to the mucosa; collection of air in the stomach may be due to negative esophageal pressure during inspiration;

Patients rely on a physician for valve replacement. Insertion technique varies according to the type of prosthesis. Widely used models, such as Provox 2 and Blom-Singer can be easily inserted in an anterograde manner, using a loading tube, in the case of the former, with the retrograde method still

available as a backup, and using a dissolvable gel cap, in the case of the latter.

The correct understanding and management of this pathology and treatment options are of utmost importance in obtaining the best possible medium and long-term outcomes. In spite of its potential shortcomings, due to its relatively easy application and short training time, tracheoesophageal speech using voice prosthesis is considered at present the „gold standard“ for rehabilitating speech in the laryngectomized patient with advanced cancer, offering superior long-term outcomes compared to other available alternatives<sup>16</sup>.

## CONCLUSIONS

From a functional, as well as psychological and social point of view, a laryngeal cancer diagnosis can have devastating consequences on all aspects of a patient's life. Phonation recovery is thus essential for psychological well-being, labour and social reintegration. Correct understanding and management of this pathology and treatment options is of utmost importance in obtaining the best possible medium and long-term outcomes. Secondary placement of the voice prosthesis provides greater oncological safety, as well as avoids common post-radiotherapy side effects.

## Author Contributions

M.T. conceived the original draft preparation. M.T. and I.T. were responsible for conception and design of the review. M.T., R.R. and D.T. were responsible for the data acquisition. M.T., R.R. and D.T. were responsible for the collection and assembly of the articles/published data, and their inclusion and interpretation in this review. All authors contributed to the critical revision of the manuscript for valuable intellectual content. All authors have read and agreed to the published version of the manuscript.

## Compliance with Ethics Requirements:

„The authors declare no conflict of interest regarding this article“

„The authors declare that all the procedures and experiments of this study respect the ethical standards in the Helsinki Declaration of 1975, as revised in 2008(5), as well as the national law. Informed consent was obtained from the patient included in the study“

„No funding for this study“

## Acknowledgements:

None

## REFERENCES

- Lorenz KJ. Rehabilitation after total laryngectomy – a tribute to the pioneers of voice restoration in the last two centuries. *Frontiers in Medicine*. 2017; 4: 81.
- Du J, Chen GG, Vlantis AC, Chan PK, Tsang RK, Van Hasselt CA. Resistance to apoptosis of HPV 16-infected laryngeal cancer cells is associated with decreased Bak and increased Bcl-2 expression. *Cancer Letters*. 2004; 205(1):81-8.
- Brook I. *The Laryngectomy Guide*. Charleston: CreateSpace Publication. 2013.
- Hakeem AH, Hakeem IH, Garg A. Rehabilitation after total laryngectomy. *Otorhinolaryngol Clin Int J*. 2010; 2: 223-9.
- Attieh AY, Searl J, Shahaltough NH, Wreikat MM, Lundy DS. Voice restoration following total laryngectomy by tracheoesophageal prosthesis: Effect on patients' quality of life and voice handicap in Jordan. *Health and Quality of Life Outcomes*. 2008; 6(1):26.
- Stafford FW. Current indications and complications of tracheoesophageal puncture for voice restoration after laryngectomy. *Current Opinion in Otolaryngology & Head and Neck Surgery*. 2003;11(2): 89-95.
- Frowen J, Perry A. Reasons for success or failure in surgical voice restoration after total laryngectomy: an Australian study. *Journal of Laryngology and Otology*. 2001; 115(5):393-9.
- Chone CT, Spina AL, Crespo AN, Gripp FM. Speech rehabilitation after total laryngectomy: long-term results with indwelling voice prosthesis Blom-Singer®. *Revista Brasileira de Otorrinolaringologia*. 2005; 71(4): 504-9.
- Serra A, Di Mauro P, Spataro D, Maiolino L, Cocuzza S. Post-laryngectomy voice rehabilitation with voice prosthesis: 15 years-experience of the ENT Clinic of University of Catania. Retrospective data analysis and literature review. *Acta Otorhinolaryngologica Italica*. 2015; 35(6): 412.
- de Coul BO, Hilgers FJ, Balm AJ, Tan IB, Van den Hoogen FJ, Van Tinteren H. A decade of postlaryngectomy vocal rehabilitation in 318 patients: a single Institution's experience with consistent application of provox indwelling voice prostheses. *Archives of Otolaryngology-Head & Neck Surgery*. 2000; 126(11): 1320-8.
- Hilgers FJ, Ackerstaff AH, Balm AJ, Van Den Brekel MW, Bing Tan I, Persson JO. A new problem-solving indwelling voice prosthesis, eliminating the need for frequent Candida and „underpressure“-related replacements: Provox ActiValve. *Acta oto-laryngologica*. 2003; 123(8):972-9.
- Rodrigues L, Banat IM, Teixeira J, Oliveira R. Strategies for the prevention of microbial biofilm formation on silicone rubber voice prostheses. *Journal of Biomedical Materials Research*. 2007; 81(2):358-370.
- Elmiyeh B, Dwivedi RC, Jallali N, et al. Surgical voice restoration after total laryngectomy: an overview. *Indian Journal of Cancer*. 2010; 47(3): 239.
- Jobe BA, Rosenthal E, Wiesberg TT, et al. Surgical management of gastroesophageal reflux and outcome after laryngectomy in patients using tracheoesophageal speech. *The American Journal of Surgery*. 2002; 183(5):539-43.
- Pattani KM, Morgan M, Nathan CA. Reflux as a cause of tracheoesophageal puncture failure. *The Laryngoscope*. 2009; 119(1):121-5.
- Malik T, Bruce I, Cherry J. Surgical complications of tracheoesophageal puncture and speech valves. *Current Opinion in Otolaryngology & Head and Neck Surgery*. 2007; 15(2): 117-22.